



**FACULTAD DE MEDICINA
UNIVERSIDAD DE CANTABRIA**

INCISION PATTERNS IN BREAST ONCOPLASTIC SURGERY



Autor: Dña. Rocío Vázquez Pérez

Director: Dr. Fernando Luis Hernánz de la Fuente

**Trabajo Fin de Grado
Grado en Medicina
Santander, junio 2015**

ABSTRACT

BACKGROUND. Oncoplastic breast conserving surgery is a modern surgical approach that allows a surgical treatment that covers oncology and reconstruction aspects avoiding cosmetic sequelae. It is a varied surgery composing of many different techniques.

OBJECTIVE. Describe the different pattern incisions used in breast conserving surgery applying oncoplastic techniques and analyse its use in a determined series of patients.

METHODS. Between 2013 and 2015, 82 patients suffering from breast cancer were operated at Department of General Surgery (Hospital Valdecilla, Santander) by comprehensive breast surgeons. Data were collected prospectively including characteristics of the patients and the tumours.

RESULTS. Data were collected from 82 women with a mean age of 59.04 (SD 6.2) years. Analysis showed both breasts were affected in similar proportions. Tumour localizations through the breast were: 32 in the upper outer quadrant, 12 upper intersection, 12 outer intersection, 10 central quadrant, 5 inner intersection, 4 upper inner quadrant, 3 lower inner quadrant and 3 in the lower intersection. We used different pattern incisions such as the Wise pattern, lateral or raquet, diamond, round block or donut, horizontal or omega and fusiform or parallelogram.

CONCLUSIONS. A prospective data collection of oncoplastic techniques demonstrated that Wise pattern was used in more than half of patients (59%). Our experience suggests that Wise pattern is a versatile pattern that can be used in all the locations.

Keywords: *breast cancer, breast conserving surgery, oncoplastic surgery, incision patterns*

INTRODUCTION

1. Breast cancer. Importance of the problem.....	3
2. Current treatment of breast cancer.....	3
3. Modern surgery for breast cancer.....	4
4. Oncoplastic surgery for breast cancer.....	4
5. Classification of the oncoplastic techniques.....	5
6. Planning.....	7
7. Pattern incision types.....	7
8. Objective.....	14
9. Patients and methods.....	14
10. Results.....	14
11. Discussion.....	16
12. Conclusion.....	17
13. Annex 1.....	18
14. References.....	24

1. Breast cancer. Importance of the problem

Breast cancer is the most common malignancy tumour and cause of death by cancer in women and the second leading cause of death overall.

The risk of developing breast cancer throughout life is 12%, with an incidence of 50-70/100,000 women per year.

According to the register of Cantabria (Registro de Tumores 2012. Dirección General de Salud Pública), 230 new breast cancers are diagnosed each year and 80 deaths occur annually (33/100.000)¹. In 2012 in Europe, breast cancer incidence was about 460.000 with a mortality of 130.000 approximately².

While the number of cases and incidence rates increase slowly, mortality rates decrease in our country, mainly due to better treatment outcomes.

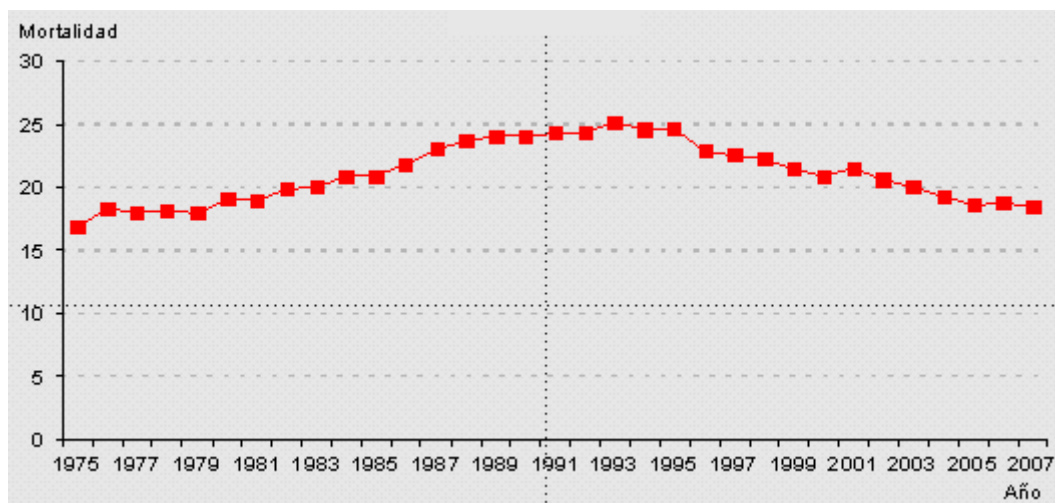


Figure 1. Adjusted mortality from breast cancer (100,000 women) in Spain from 1997 to 2007 ³

2. Current treatment of breast cancer

The first surgical treatment with a scientific basis was carried out in 1882, when Halsted designed an intervention called *radical mastectomy*. This surgery was performed throughout the twentieth century, with a cure rate of 40% for those patients with a mechanical extension from the tumour to the lymph nodes, then to the blood and finally metastasis. This technique consisted of removing all the skin around the breast, fat, breast tissue, lymph channels and pectoral muscles, leaving only the rib cage and causing a large defect, which today is seen as a very aggressive surgery.

Since then, resections have become increasingly smaller and more efficient. In the 1970s, Veronesi showed that conservative surgery (removing the tumour with free margins while preserving the breast) plus radiotherapy gave the same survival results as more aggressive surgeries.⁴

3. Modern surgery for breast cancer

From Halsted mastectomy to modern techniques, surgery has evolved, individualizing treatment based on tumour (stage, location, etc.) and patient's characteristics (breast size, shape, etc.), representing the emergence of different surgical techniques named *oncoplastics*.

Therefore, surgeons must be included within a multidisciplinary team in planning individualized treatment, acting on the breast or axilla looking for cure or palliation. Nevertheless, surgery is a fundamental pillar to achieve good cosmetic results. In this context, the concept of "complete breast surgeon" appears, referring to the one who knows and manages oncologic and plastic techniques.

Modern surgery is patient-centred and has many technical possibilities, while maintaining oncologic principles and bearing in mind the aesthetic and functional sequelae that will affect the quality of life of the patient.

The surgeon should always avoid a resection with inadequate surgical margins, wrong axillar nodal status staging, loss of therapeutic opportunity and both functional and aesthetic sequelae.

The nodal status can be assessed by several techniques such as ultrasound and biopsy, axillary lymph nodes dissection or axillary sampling, but the most used today is sentinel node biopsy.

4. Oncoplastic surgery for breast cancer

Plastic surgery techniques were transposed into breast-conserving therapy to avoid late unsatisfactory aesthetic results in 1980s in France by Jean-Yves Petit (Institut Goustave-Roussy), Jean-Yves Bobin (Centre Léon-Bérard) and Michel Abbes (Centre Lacassagne).⁵ However, Audretsch, considered by some as the father of oncoplastic surgery, described the technique of reconstructing a partial mastectomy defect in 1998 as a further refinement of breast conservation avoiding mastectomy, coining the term *oncoplastic*.⁶

In the last 15 years, more than 400 publications have been published in PubMed related to oncoplastic surgery and, since its introduction, several authors have given different definitions of this term adding new nuances as the technique has evolved.

Alexandre Munhoz describes the modern oncoplastic breast surgery as a combination of oncologic and plastic surgery techniques to obtain oncologically sound and aesthetically pleasing results. Thus, by means of customized techniques the surgeon ensures that oncologic principles are not jeopardized while meeting the needs of the patient from an aesthetic point of view.⁷

Krisna Clough defines oncoplastic surgery as a new approach to allow wide excision for breast conservation surgery without compromising the natural shape of the breast. It is based upon integration of plastic surgery techniques for immediate breast reshaping after wide excision for breast cancer.⁸

Cicero Urban adds that oncoplastic and reconstructive surgery combines the most up-to-date techniques in plastic surgery with surgery for breast cancer, providing optimal oncologic and aesthetic results by means of a single procedure.⁹

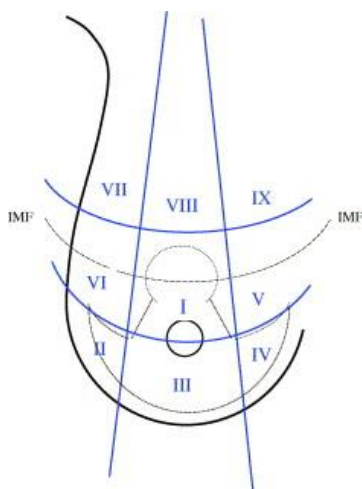
Through the years, oncoplastic breast surgery has enabled surgeons to remove greater volumes of tissue successfully, and thus reducing mastectomy and re-excision rates.

5. Classification of the oncoplastic techniques

Oncoplastic techniques can be classified in two large groups: volume displacement procedures and volume replacement procedures.

Volume displacement procedures combine tumoral resection with immediate reconstruction of the mammary defect caused by the resection. They are indicated when a resection of less than 30% of mammary volume is preview. These include techniques of glandular rearrangement (advancement, rotation or transposition glandular flaps) and reduction mammoplasties.

Glandular rearrangement consists in mobilize the surrounding tissue of the resection area to fill the defect. It is used for resections of less than 10% of breast volume if the location of the lesion is medial to the tumour. In case of lateral tumours, it can be used to cover defects up to 20% of breast volume



“Therapeutic mammoplasty” is a term coined by McCulley and Macmillan¹⁰ which refers to a reduction mammoplasty technique supplemented with radiotherapy to treat breast cancer. These authors describe two scenarios depending on if the tumour lies or not within the routine pattern excision site of a regular mammoplasty method. These excision sites are classified in nine areas with their corresponding approaches.

Figure 2: Zones of the breast orientated around the proposed mammoplasty markings.¹⁰

Volume replacement procedures use autologous tissue flaps to replace the excised breast volume. The most used is the *latissimus dorsi* flap with or without skin. It allows the restoring of the shape and size of the breast symmetry, achieving excellent cosmetic results without the need to act on the contralateral breast. These techniques are usually reserved for patients requiring extensive local resections, those that present medium or large tumours, and those who do not wish volume loss or surgery in the healthy breast.

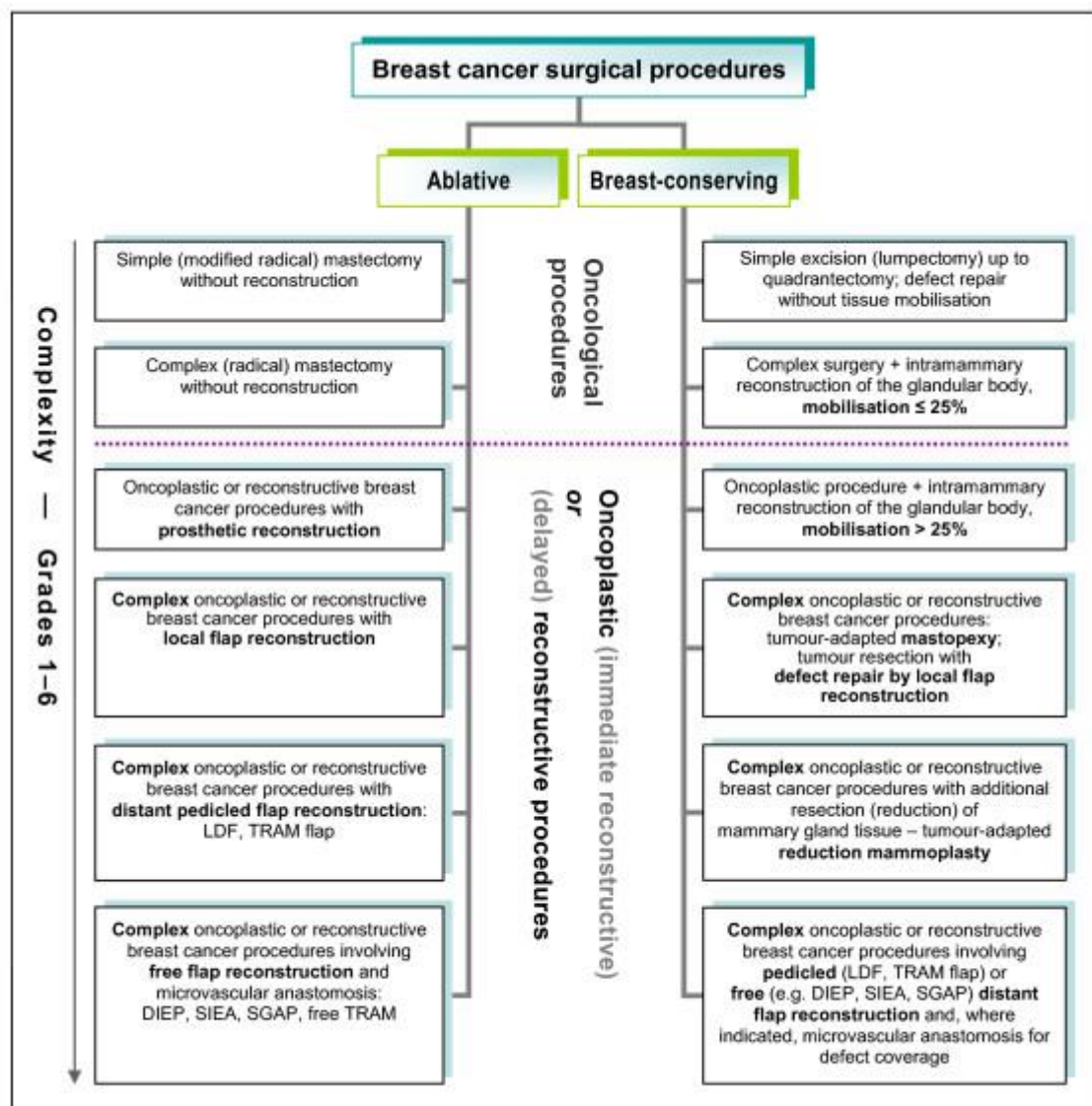
In order to improve surgical trainees, Urban¹¹ developed a classification based on three skills:

- **Class I:** monolateral breast reconstruction techniques such as aesthetic skin incisions, deepithelization of the areolar margins, glandular mobilization and

reshaping techniques, purse string sutures for central quadrant reconstruction, and immediate breast reconstruction with temporary expanders. Specific competence in plastic surgery is not required at this point.

- **Class II:** bilateral procedures such as immediate and delayed breast reconstruction with implants, lipofilling, breast augmentation, breast reduction, mastopexy, Grisotti flap, and nipple and areola reconstruction. Specific competence in plastic surgery techniques of the breast is required to achieve better symmetry.
- **Class III:** more complex monolateral or bilateral procedures involving autologous flaps (pedicled or free flaps) or a combination of techniques. A higher standard in plastic surgery techniques is required.

Hoffmann and Wallwiene describe a different system based on six levels of complexity of oncological, oncoplastic and delayed reconstructive surgery.¹²



The aim of this study is to describe the different patterns used in breast conserving surgery applying oncoplastic techniques and, specifically, those procedures that use volume displacement techniques.

6. Planning

The first aspect that needs to be considered when planning an oncoplastic surgery is that it has to be individualized, basing the decision of the technique that will be used on several elements: tumour location, size of the breast, ptosis and density. The surgeon's preference is an important factor as well.^{13,14}

Tumour location

There are zones that are at high risk of deformity during breast cancer surgery (BCS). The upper outer quadrant of the breast is a favourable location for a large-volume excision. On the other side, lower pole or upper inner quadrants of the breast often creates a major risk of deformity.

Breast size

There are some patterns that are indicated for big sized breast, since a large amount of tissue will be excised, like reduction mammoplasties. On the other hand, round block or rotation patterns are better indicated for small or medium sized breast.

Glandular density

It is evaluated clinically and radiographically (mammographic evaluation is a more reproducible approach). Breast density predicts the fatty composition of the breast and determines the ability to perform extensive breast undermining and reshaping without complications.¹⁵

7. Pattern incision types

Now, different incision patterns will be described attending to the pattern scheme, preferential location of the lesion to be excised, advantages, disadvantages and complications.

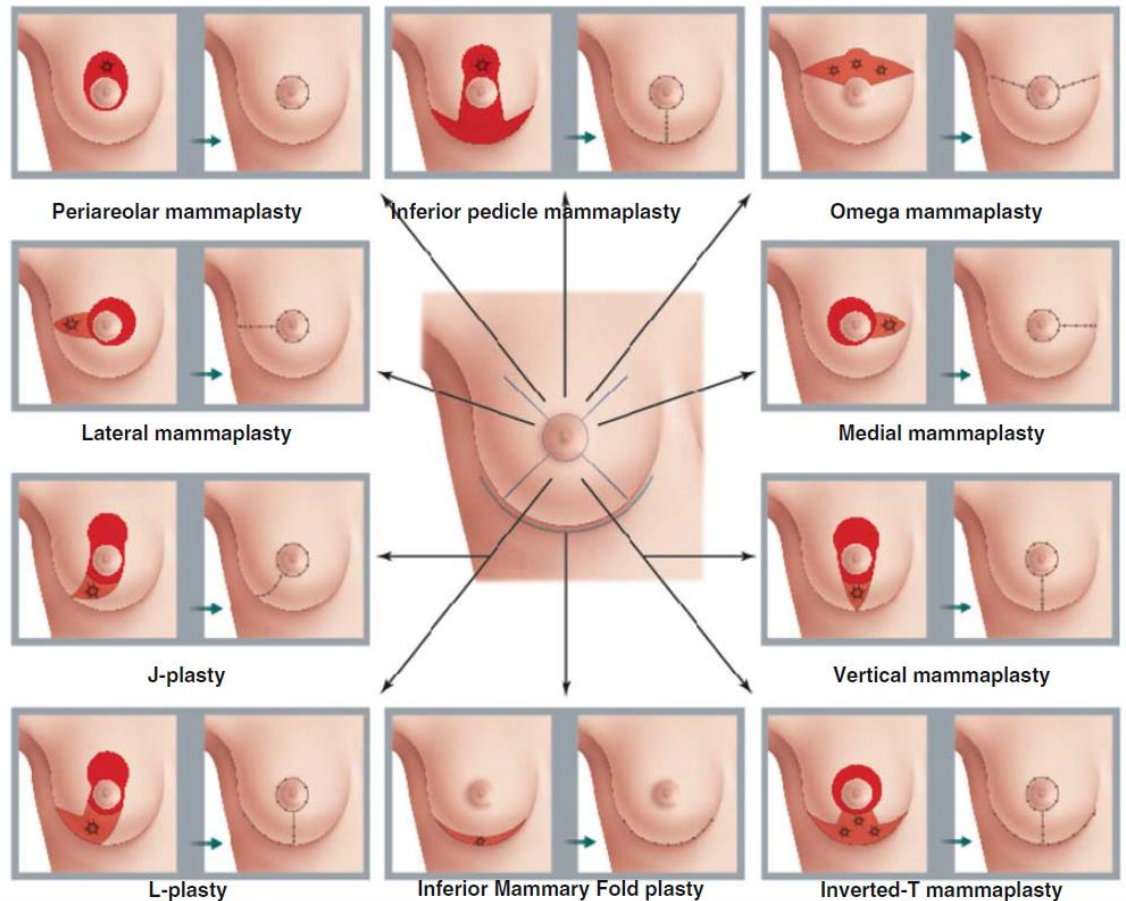
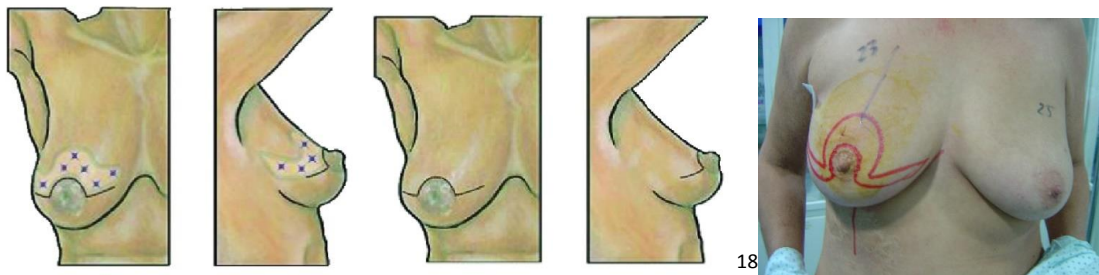


Figure 3: Selection of Oncoplastic Breast Surgery technique according to tumour location¹⁷

7.1 Batwing resection

Synonyms: Horizontal mammoplasty, omega mammoplasty

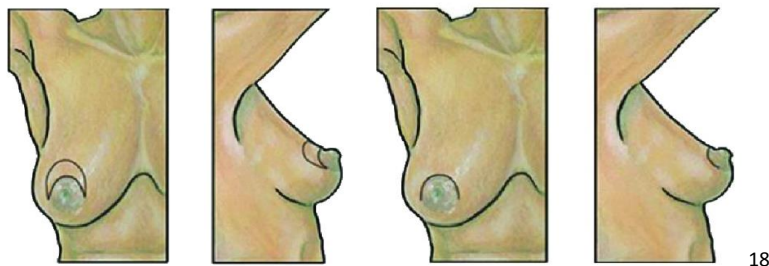


The goal of the horizontal mammoplasty is prevention of deformities in the upper pole of the breast, especially those occurring in breast midline in the vicinity of NAC (Nipple Areola Complex). It is also an effective technique in preventing deformities caused by retraction of NAC in tumours located in his nearness. It is also safe and useful in breasts which have been previously radiated since it does not undermine.

This pattern is suitable for those neoplasms on the upper pole, and it finds its best indication in medium size breasts with a moderate ptosis because in these situations its role as mastopexy is accentuated by offering the best aesthetic results.¹⁹

Horizontal mammoplasty is an accessible procedure from a technical point of view, simple in its planification, low incidence of complications, and a moderate impact in the body image of the patient. In addition, technical simplicity in implementation, similar to a quadrantectomy, does not significantly increase the duration of surgery. Moreover, this technical simplicity and low incidence of complications will allow outpatient management or short stay of the patient, especially when axillary sentinel node biopsy is associated. Finally, there is an added advantage when used only in the sick breast in order to avoid local deformities in women who require a conservative management and whose contralateral symmetrization is not planned, either by requiring women or medical contraindication.²⁰

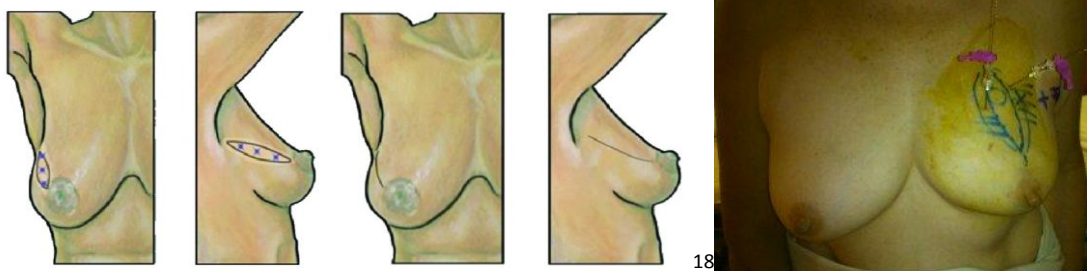
7.1.1 Crescent mastopexy



It is a variant of the batwing pattern. The crescent mastopexy resection allows removal of a tumour in the central breast superior to, but not involving, the nipple or areola. The crescent mastopexy resection consists of a crescent-shaped area of skin and glandular tissue excised from the superior border of the areola, which has the effect of elevating the NAC and inferior breast and achieving mild correction of ptosis. As an alternative to the standard circumareolar incision, the principle oncological advantage of the crescent mastopexy resection is the removal of skin overlying a tumour in the superficial breast, thus ensuring a clear superficial margin.

7.2 Parallelogram mastopexy

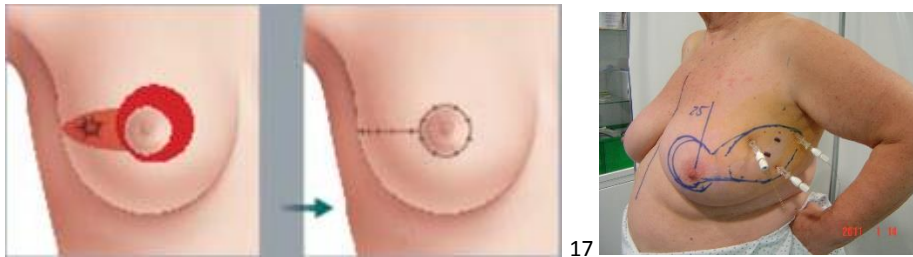
Synonyms: *radial ellipse segmentectomy, diamond pattern.*



Parallelogram mastopexy is applicable when the tumour is located far from the NAC, and this allows for larger margins compared to standard lumpectomy. The disadvantage of this pattern is an increased scar length, and care must be taken against removing too much skin to broadly prevent shifting of the NAC, so this procedure can be used in small tumours.

7.3 Tennis racquet resection

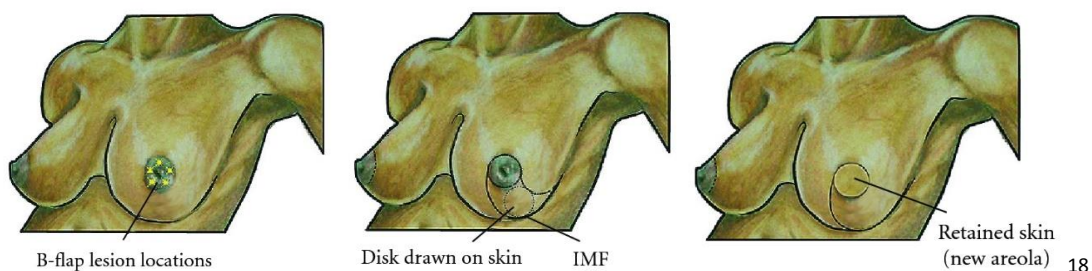Synonyms: lateral mammoplasty



Tennis racquet resection allows surgery over upper outer quadrant, and its final goal is to prevent deformities originated after tumour exeresis. This pattern is a segmentary quadrantectomy from the NAC to the axilla and it is complemented with a medial movilization of the NAC. This pattern produces a lateral reduction of the mammary outline that results in a rounder breast.

This pattern is not frequently used because its indication is very limited to a small anatomic area. The best indication is a tumour situated in the external interquadrant area, between the NAC and the axilla, in women with medium sized breast and mild ptosis.

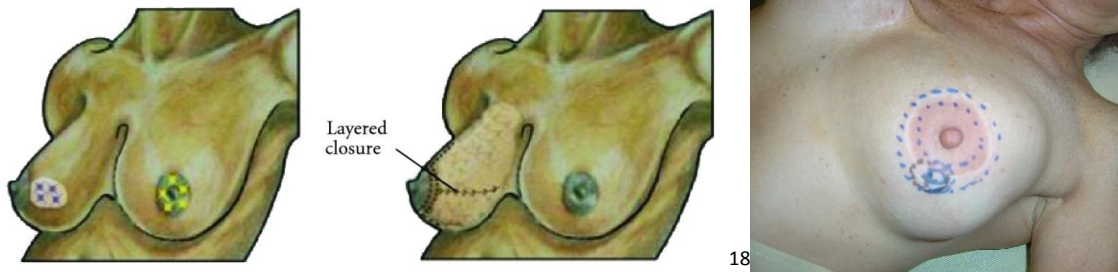
7.4 B-flap resection or Grisotti flap



This tecnique is indicated when the tumour is located close to the NAC and it is necessary to reconstruct the central breast in a woman with enough breast volume or moderate breast ptosis. The B-flap resection is named for the “B” shaped incision that is created to resect and reconstruct the breast. The circumareolar incision makes up the upper portion of the “B” and the lower portion of the “B” is defined by a disk of skin from the lower part of the breast that is preserved and transposed (along with an inferior pedicle of glandular tissue) to the central breast to replace the resected areola and reconstruct the central breast defect. The resulting surgical specimen is comprised of the NAC and the central cylinder of glandular tissue extending to the *pectoralis* fascia.

7.5 "Round-block"

Synonyms: circular mammoplasty, donut mastopexy, Benelli technique, periareolar mammoplasty

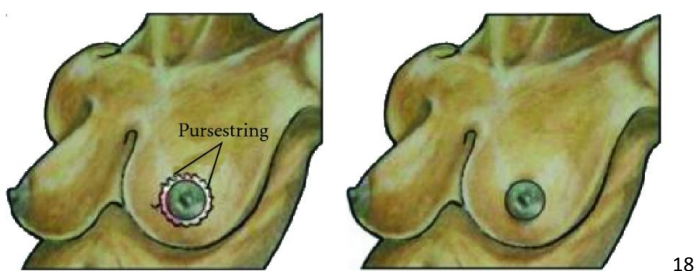


The round block pattern can be used in patients with small-to moderate-sized breasts without ptosis and for tumours located near the NAC but without nipple invasion. Removed volume is not usually bigger than 50 g, so it is not necessary a contralateral symmetrization. If necessary, as in severe ptosis, the opposite NAC may be repositioned using the same method to result in a symmetric and ideal position of and appearance of the NAC. After the surgery, the cosmetic results are satisfactory because there are only perimamillary scars without any additional scars, and in the case of a large NAC, a smaller neo-areola may be created.

The main target of this pattern is the decrease of the mammary projection with a minimum effect on the size and height of the NAC.

From the oncological point of view, this pattern is limited to smaller tumours than 2 cm, because it doesn't allow large glandular resections. It is a good pattern for those patients that require symmetrization surgery just to relocate the NAC.

7.5.1 Purse-string suture



It is a variant of the round block pattern. A purse-string suture is used when the tumour is located close to the NAC, and the NAC is excised along with the tumour. Round defects after central quadrantectomy are brought together after undermining the nearby breast tissue, and the skin is closed by a continuous running stitch pattern using purse-string sutures. This pattern should only be performed when the defect is small enough to be closed using nearby breast tissue. In the past, close proximity of the tumour to the NAC was an indication for total mastectomy. Using purse-string sutures can yield satisfactory cosmetic results by conserving the breast, reconstructing the NAC and tattooing after radiation therapy.

7.6 Therapeutic mammoplasty

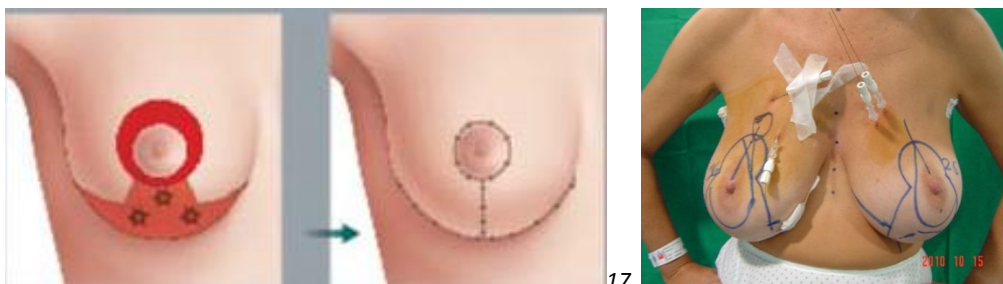Reduction mammoplasty is an oncoplastic technique that may be used if the patient has a large or ptotic breast, and it is usually performed using two different incision patterns (Wise pattern and vertical mammoplasty). Patient selection should be primarily limited to those who desire breast reduction and those who have at least moderately sized breasts with a defect that is suspected to be at least moderate in size.

Therapeutic mammoplasty has many cosmetic, functional, and oncological advantages. Because the breast size decreases after the procedure, the balance of the two breasts against each other and against the entire body can be optimally maintained. Back and shoulder pain due to large breasts can be resolved, and a more balanced posture can be achieved. In addition, investigation of the excised parenchymal tissue from opposite breast allows for the detection of occult breast lesions. By reducing the breast size, the use of postoperative radiation is made easier, and radiotherapy complications can be meaningfully decreased by using equal amounts of radiation in a well-balanced distribution.

The location of the tumour is thought to be the most important factor in the choice of a pedicle used to move or traslate CAP. An inferiorly based pedicle is used if the tumour is located in the upper breast, and the superiorly based pedicle is used if it is located in the lower breast. The preferred patterns and tendencies of the surgeon and the preference of the patient can influence the decision. In the case of moderate-sized breasts, a vertical pattern or Wise pattern can be chosen based on breast size, degree of ptosis, and size of the tumour to be excised. For larger breasts, the Wise pattern is primarily used.

7.6.1 Vertical mammoplasty with double branch

Synonyms: Wise pattern, inverted T



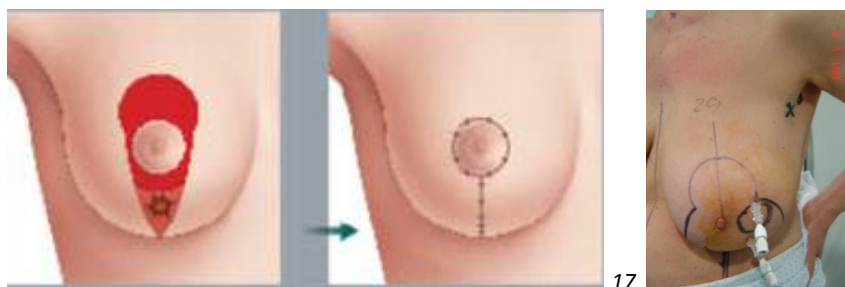
This pattern is indicated to prevent deformities in the lower pole, especially in voluminous breasts, and reduce the toxicity caused by radiotherapy in ptotic breasts. It is, therefore, indicated in medium or big sized breast (with resections of 200-1000g) with moderate or severe ptosis. From the oncological point of view it is indicated in tumours located in the lower pole that can be multicentric, since a large amount of tissue will be excised. It can be also indicated in tumours located in the upper pole (or the intersection of upper quadrants close to the NAC) by using a pedicle of the lower pole.

The main disadvantage of this pattern is the absence of volume and ptosis since in this cases, it will result in a depleted breast with an excessively raised NAC. It must be considered that this is a more complex pattern in its planification [planning?], execution and resolution of its complications, so it is not recommended for surgeons without enough experience in reduction mammoplasty techniques

The *Wise pattern* is the most commonly used incision for reduction mammoplasties which offers the surgeon wide access to the breast parenchyma and allows skin excision in both vertical and horizontal dimension, and can be used with any pedicle.

7.6.2 Superior pedicle vertical mammoplasty with single branch

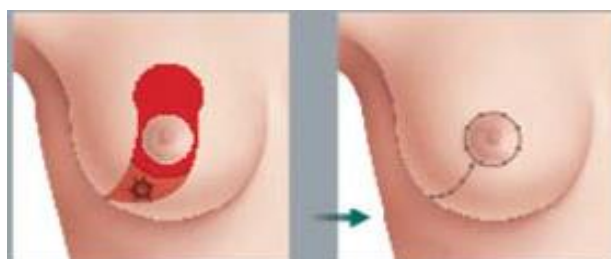
Synonyms: *Lejour mammoplasty, vertical reduction mammoplasty*



The main target of the vertical mammoplasty is to maintain the NAC after the excision of the tumour in the lower pole. Because this excision usually leaves a breast with conic shape and higher NAC, it is specially indicated in small or medium sized breasts with mild or moderate ptosis (especially in young women). The main indication of this pattern is the excision of tumours at the intersection of lower quadrants. If the lesion is retroareolar and it is necessary to excise the NAC, it is possible to reconstruct the complex with the Grissotti's technique.

The main disadvantage of this pattern is the size of the breast, since small breasts without ptosis would result as flat breasts with excessively high NAC. Voluminous breast with big ptosis aren't an indication neither, since a vertical mammoplasty with double branch can decrease the toxicity of the postoperative radiotherapy. From the oncological point of view, this pattern is not indicated in multicentric or diffuse processes, since it is a pattern with limitations for margins enlargement.

.6.3 J-mammoplasty



This pattern is ideal for tumours located in the inferior or inferolateral quadrants. The vertical incision below the areola is extended laterally, allowing limitation of the

inframammary scar in large-volume breasts. This pattern sits between a pure vertical-scar and an inverted-T mammaplasty.²¹

8. Objective

The aim of this work was to analyse the patients that were operated at the Breast Unit of Department of General Surgery (HUMV, Santander, Spain) with breast conserving surgery techniques between 2013 and 2015, describing the different incision patterns used.

9. Patients and methods

An observational study was made with a group of patients from the screening program for breast cancer of Cantabria and patients that were diagnosed by other ways. Data of all patients were collected prospectively.

Between 2013 and 2015, 82 patients suffering from breast cancer suitable for BCS were operated at the Breast Unit.

The following variables were entered in a database (SPSS) for analysis:

- Age of the patient (years)
- Date of surgery
- Date of histological diagnosis
- Menstrual stage: pre/postmenopausal
- Affected breast: right/left breast or bilateral
- Location of the tumour through the breast: four quadrants, their intersections, central position and inframammary fold
- Multifocal: several tumour foci in the same quadrant or less than 4-5 cm between them (Yes/No)
- Multicentric: several tumour foci in different quadrants or more than 4-5 cm between them (Yes/No)
- Radiological measure: echography, mammography or magnetic resonance
- Infiltration: in situ/ infiltrating
- Histological type: ductal, lobular, mixed, papillary, medullary, solid, other
- Type of surgery: tumorectomy, partial mastectomy
- Incision pattern: lateral, horizontal, round block, Wise, diamond, fusiform and others

10. Results

Table 1. Characteristics of patients and tumours.

- Age of patient (years)
 - o Mean: 59.04
 - o SD 6.2
- Menstrual stage
 - o Premenstrual: 12 (14,6%)
 - o Postmenstrual: 70 (85,4%)

- Multifocal
 - Yes: 14
 - No: 68
- Multicentric
 - Yes: 2
 - No: 80
- Radiological measure
 - Ecography: 1
 - Mammography: 27
 - MR: 62
- Infiltration
 - In situ: 7
 - Infiltrating: 75
- Type of surgery
 - Tumourectomy: 64
 - Partial mastectomy: 12

In terms of tumour location, the results are shown in Figure 1. Upper outer quadrant was the most frequent location (39.5%)

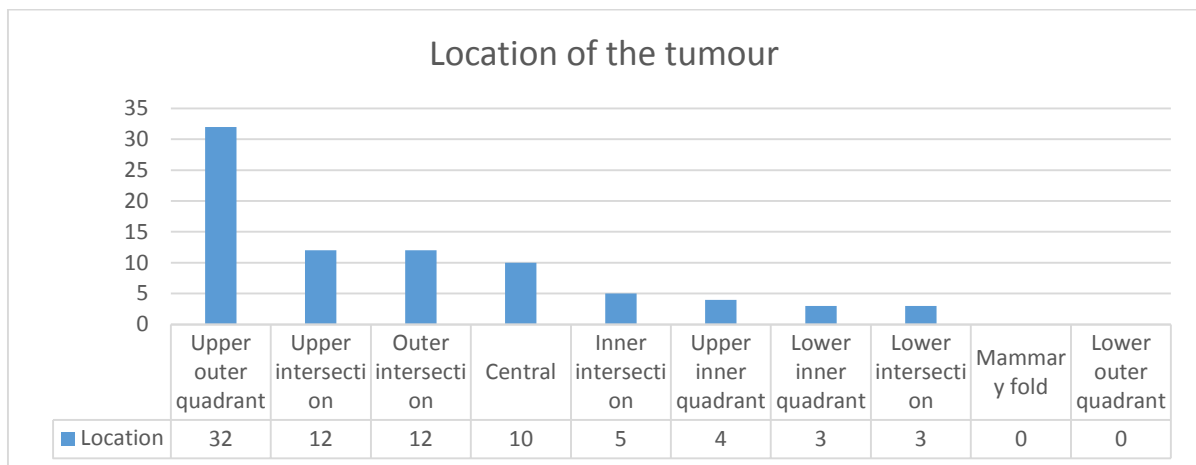


Figure 4: Location of the tumour

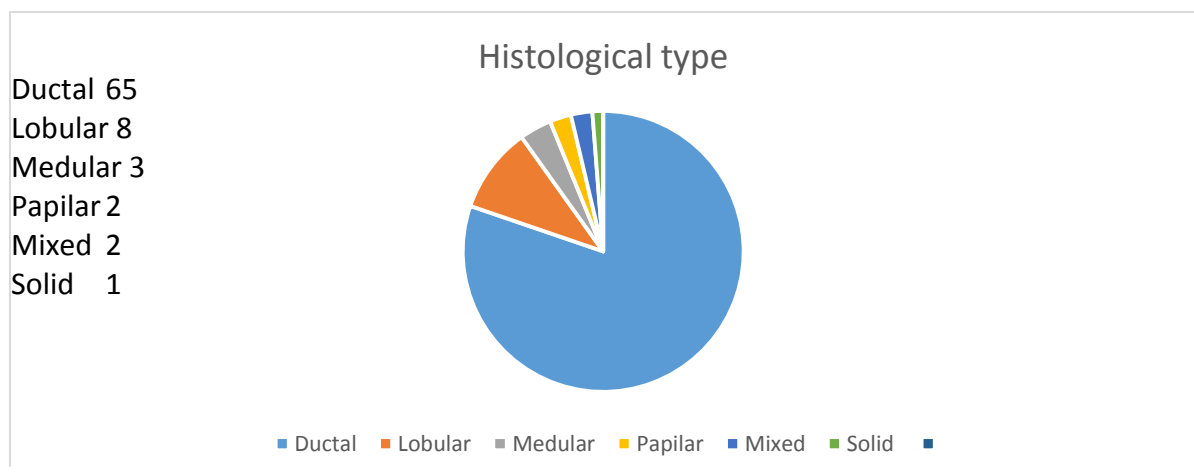


Figure 5: Histological type

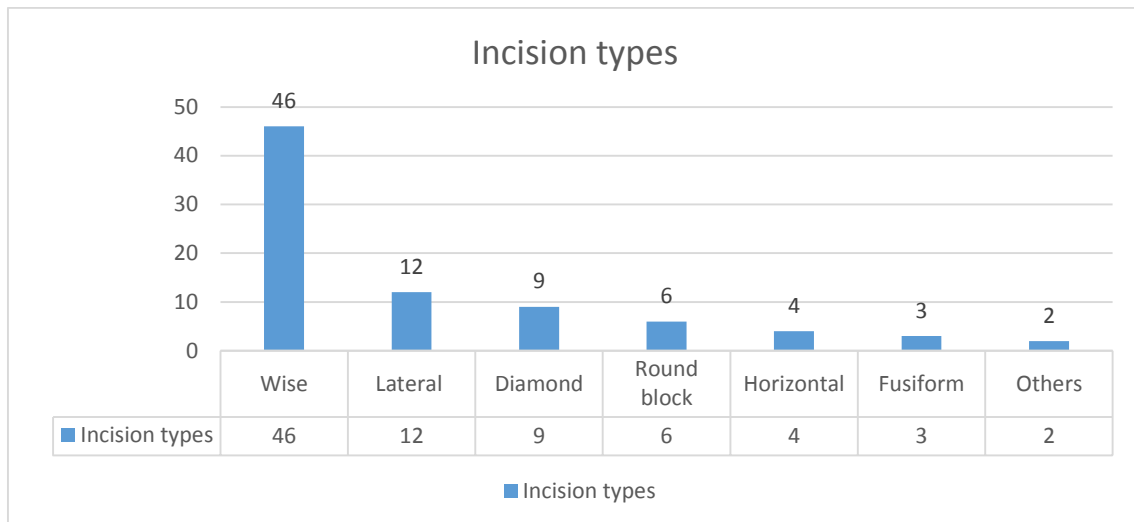


Figure 6: Incision pattern

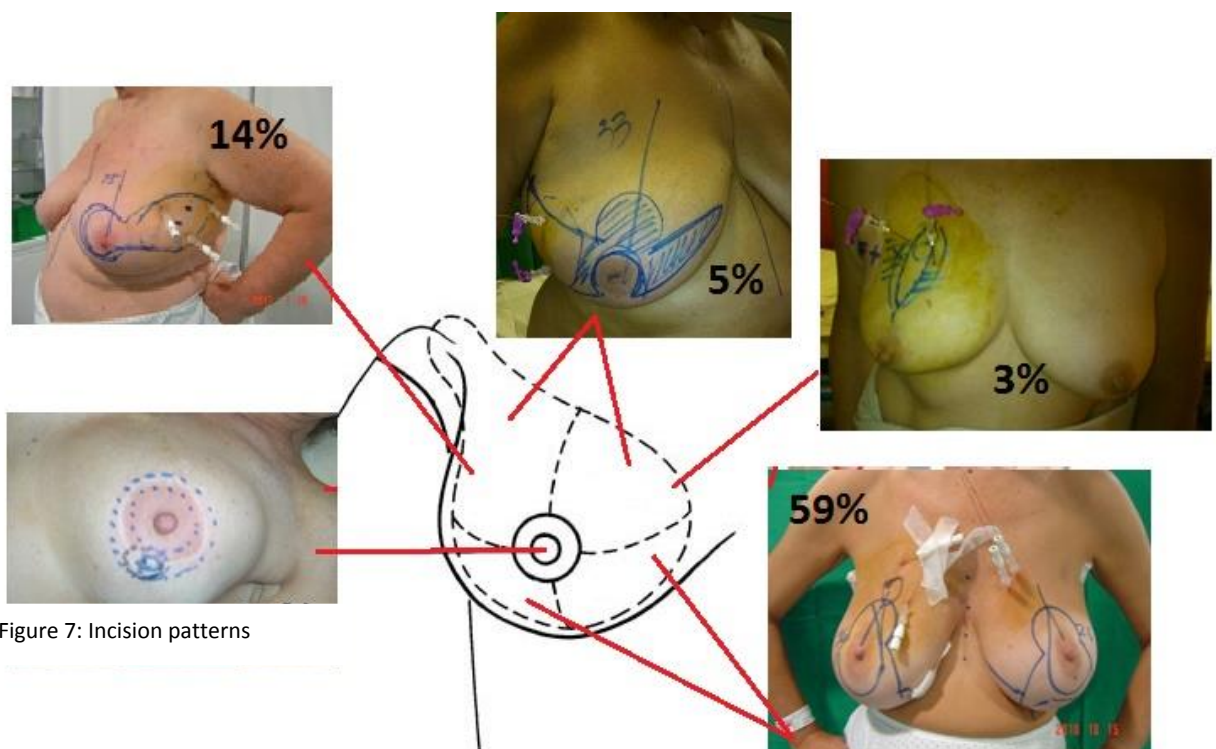


Figure 7: Incision patterns

11. Discussion

As it can be seen in Table 1, the age of the patients is atypically high, with a large number of postmenopausal women. This can be explained since the most of the patients came from a screening program, which includes patients from 50 to 70 years old.

There are several incision patterns that can be used in oncoplastic surgery. Patterns are usually selected depending on the location of the tumour, the breast size and the surgeon preferences. In our series, we used Wise pattern (56,09%), lateral pattern

(14,63%), diamond pattern (10,97%), round block (7,31%), horizontal pattern (4,87%) and fusiform pattern (3,65%).

Although some of the patterns are preferably used in certain locations like racket pattern in the upper outer quadrant²² or round block pattern in the vicinity of the NAC²³, Wise pattern can be used to treat tumours located at all breast quadrants. In a very large series of 540 consecutive cases published by Fitoussi AD²⁴ in which a variety of patterns were used, Wise pattern was the most frequently used in 40% of patients. In our analysis this pattern incision is the most common (Figure 6) used in 56,09% of cases.

12. Conclusion

Oncoplastic surgery allows treating patients with breast cancer conservatively, leading the intervention only to their tumour and thus keeping the rest of the breast with a suitable shape and size from the aesthetic point of view, reaching the oncological outcome sought (after adding a postoperative radiotherapy). To this end it has different surgical techniques of displacement and replacement of tissues that can be made with different scoring rules mainly considering the size and location of the tumour, morphology of the breast and surgeon preferences. There are patterns designed exclusively for an exact location, so that the frequency of use depends primarily on the prevalence of the tumour with specific features that allows to apply them. However, in our series, we have seen that the Wise pattern can be used in several locations and several types of tumours, which gives it great versatility.

ANNEX 1 *(publication pending)*

Versatility of therapeutic reduction mammoplasty in oncoplastic breast conserving surgery.

Authors.

Fernando Hernanz MD PhD,

Mónica González-Noriega MD,

Rocio Vazquez Perez

Manuel Gómez-Fleitas MD PhD

Oncoplastic Breast Surgery Unit.

Valdecilla Hospital, Avda. Valdecilla sn, 39008 Santander; Spain

Abstract

In our current practice therapeutic reduction mammoplasty is our preferred oncoplastic breast conserving approach, which we utilize in almost half of our patients. This technique is very versatile and allows us the resection of tumors located in all breast quadrants of patients with moderate-to large-sized breasts. We describe a series of 57 patients who were treated using a therapeutic reduction mammoplasty. Surgical margins were insufficient in eight patients (14%). Nine patients (15.8%) had a complication in early postoperative period and in one, adjuvant radiotherapy was delayed four months due to a wound dehiscence. The rate of synchronous contralateral symmetrization was 31.6% . We conclude that reduction mammoplasty is a useful and safe method to treat breast cancer conservatively. Therefore, reduction mammoplasty must be considered a priority when setting learning objectives.

Introduction.

Currently, oncoplastic breast conserving surgery (OBCS) is the gold standard approach for the surgical treatment of early breast cancer ⁽¹⁻³⁾. Oncoplastic techniques (OT) offer clear advantages for the nearly forty percent of patients in whom common breast conserving treatment (BCT) (surgery plus radiotherapy) are currently followed by cosmetic sequelae⁴ besides the additional patients who could also benefit from many surgical techniques which can improve aesthetic outcomes⁵. Since 1998, when W. Audretsch⁶ described the use of plastic surgery techniques to reshape the breast at the time of lumpectomy or quadrantectomy and

introduced the term “oncoplastic”, enough time has passed to evaluate long-term oncologic outcomes. A meta-analysis of 3165 patients treated by OCBS and 5494 treated by BCT demonstrates that OCBS shows similar results to standard breast conserving surgery, improves cosmetic outcome and patient satisfaction⁷.

There are a large number of OT, but these can be classified in two main groups: volume replacement and displacement techniques. Nowadays, it is the latter that are more frequently used⁸, have a broad technical variety with different patterns incisions, pedicles used for nipple areola complex (NAC) movement, ways to fill tumor removal defect and their multiple combinations. Several authors⁽⁹⁻¹³⁾ have created algorithms for attempting to optimize OT, offering us a method to select the most appropriate OT in each patient. These algorithms for immediate conservative surgery reconstruction are based on some aspects such as type and size of the breast, extent of tumor removal defect, ptosis degree, breast tissue density and location of the tumor in the breast. Other aspects very important in the process of decision are patient preferences and surgeon expertise.

In the OT displacement volume group, there is well defined technique of “therapeutic mammoplasty”, a term coined by McCulley SJ and Macmillan RD^{14,15} which is characterized by using a reduction mammoplasty technique and radiotherapy to treat breast cancer. These authors describe two scenarios depending on if the tumor lies or does not lie within the routine pattern incision and excision dividing the breast into nine areas with their corresponding approaches. Therapeutic mammoplasty is especially useful in large breasted patients in whom a bilateral reduction mammoplasty offers clear advantages, which are both oncological and functional, and enable radiation therapy while relieving the symptoms related to breast hypertrophy thus improving quality of life¹⁶. Furthermore, this approach is a better option than skin-sparing total mastectomy and immediate reconstruction having lower morbidity and more favorable cosmesis¹⁷.

Munhoz AM¹⁸, wrote that the main advantages of the therapeutic reduction mammoplasty (TRM) should include reproducibility, low interference with oncological treatment and long-term results. We agree completely with Munhoz and, what is more, based on our experience, we would like to add that this technique is versatile because it can be used to treat tumors located in all breast quadrants with the condition where the patient has a moderate to large-sized breast.

The aim of this paper is to communicate our experience with TRM showing the distribution of tumors in the breast, rate of affected margins, early surgical complications, and synchronous contralateral breast symmetrization.

Patients and methods.

Between 2005 and 2013, 57 patients suffering from breast cancer suitable for BCT underwent TRM at our Oncoplastic Breast Unit, Hospital Valdecilla (Santander, Spain). All surgical procedures were carried out by one comprehensive breast surgeon (F.H) who planned and designed the surgery and performed both oncologic and reconstructive procedures. Data from patient and tumor characteristics, surgical procedures, early complications, and pathological study were prospectively collected and stored in IBM SPSS statistics program.

Results.

Characteristic of patients and tumours are described in Table 1. Seven patients were treated before surgery with neoadjuvant chemotherapy. Most tumor excisions were guided by needle-wires (84.2%), according to our method previously published¹⁹, where wires are inserted 1 cm distant from radiologic tumors limits as markers of optimal limit resection and sufficiency of resection margins is per-operatively tested by X-ray analysis of the surgical specimen. Biopsy of sentinel lymph node (49) and axillary linfadenectomy (10) was performed in mostly patients by the T inverted pattern incision. Opposite breast surgery by reduction mammoplasty was carried out in eighteen patients (31.6%).

Surgical margins status.

Margins were insufficient in eight patients (14%), five affected and three with focal involvement. Two patients with affected margins underwent total mastectomy. Pathologic study of mastectomy showed residual invasive carcinoma and carcinoma in situ in one patient and residual ductal carcinoma in situ in the other.

Early surgical complications.

Nine patients (15.8%) had a complication in early postoperative period (five a hematoma, four a minor wound dehiscence) and three had to be re-operated to evacuate a hematoma. There were no major complications such necrosis of NAC or severe breast infections and in only one patient was adjuvant radiotherapy was delayed for four months due to a wound dehiscence.

Discussion.

Although some OT are specifically useful to manage some determined tumor locations such as a lateral or tennis racket mamamplasty²⁰ for tumors located at upper outer quadrant or LIQ-V mammaplasties²¹ for those located at lower inner quadrants, reduction mammaplasty with T inverted pattern incision, appropriately adapted, is be able to treat tumors situated in all breast quadrants. In a very large series of 540 consecutive cases published by Fitoussi AD²² in which a variety of OT were used, T inverted pattern incision was the most frequently utilized; being used in 40% of patients. In our current oncoplastic breast conserving experience using the volume displacement technique, this pattern incision is the most common (Figure 1) being used in 52% of cases, and our preferred approach (unpublished data).

As inner quadrants were the less frequent tumor localizations, being 10.6% of cases, and the those in the outer quadrant were the more frequent, our first choice to move NAC was a superomedial pedicle but in this series we also used inferior and bipedicled pedicles. In those patients with central tumors in whom NAC had to be removed, we reconstructed NAC using different techniques, for example, contralateral areola (Figure 2) or skin graft plus arrow flap for nipple reconstruction. The variation of localizations shows the versatility of TRM in breast with moderate or large size.

Early complications rate was 15.8%.and these were minor. Our experience is similar that described elsewhere, such as Gulceilk MA et al.²³ who report a rate of minor early complications of 16.3% and major complications of 1.9% without differences between reduction mammaplasty used for macromastia treatment and breast cancer. A wide range of complication rates of therapeutic reduction mammaplasty has been reported²⁴. This is likely due to differences in criteria and data collection. However, one conclusion is uniform: that complications are usually minor and not impacting seriously on delivery of adjuvant therapies

unless they were severe. McIntosh J and O'Donoghue JM²⁵ reports a systematic review that finds delayed adjuvant treatment in only 6% of cases.

The rate of synchronous contralateral symmetrization was 31.6% but most of these patients were operated in the first half of the series before 2011. As concluded in Fitoussi AD et al²², our current preference is delayed contralateral symmetrization. The reasons for this have been clearly exposed in Kaviani A and Safavi A²⁶ which categorized patients in three groups: patients unwilling to undergo any contralateral procedures, patients preferring an all-in-one operation with immediate symmetrization and patients desiring optimal aesthetic results. Only patients belonging to the second group are candidates to immediate contralateral symmetrization. In our estimation, our average patient is in the first group. Figure 3 shows the appearance of a patient belonging to third group with breast asymmetry, which she wants to be corrected. We will carry out symmetrization of the right breast when she stabilizes her weight gained during chemotherapy treatment.

Patient satisfaction and aesthetic outcomes reported are very high with a low rate of failure as summarized by the fact that almost no patients regret choosing this type of surgery¹⁸. Changes of aesthetic outcomes over the time after completing radiotherapy have been commented as not affecting negatively patient satisfaction. In our experience, TRM as a reduction mammoplasty technique has the same limitations and aesthetic outcomes and can be deteriorated over the time by pseudoptosis (Figure 4) or excessive weight gain.

Finally, all OT and, more specifically, those of level II, are based on the knowledge of reduction mammoplasty techniques. Which ever model of oncoplastic approach is chosen by the "comprehensive breast surgeon" or "oncologic and plastic team", skill sharing between breast unit members is desirable and skill sharing about reduction mammoplasty techniques is essential. Accepting the lack of oncoplastic training²⁷ and the fact that expertise requires long time to establish²⁸, we proposed a management policy²⁹ to mitigate this situation by incorporating the surgical treatment of symptomatic macromastia into Breast Cancer Unit³⁰. One step in this direction is the inclusion of gynaecomastia and congenital asymmetry surgical treatment into several Oncoplastic Breast Surgery Units in United Kingdom.(ref?)

Conclusion.

Reduction mammoplasty technique is a useful and safe skill to treat breast cancer located in all breast quadrants with low morbidity playing a very important role in oncoplastic conservative surgery in moderate to large breasted patients. Therefore, it must be situated in the priority of learning objectives.

References.

1. Warren AG, Morris DJ, Houlihan MJ, Slavin SA. Breast reconstruction in a changing breast cancer treatment paradigm. *Plast Reconstr Surg* 2008; **121**:1116-1126. DOI: 10.1097/01.prs.0000305516.93441.fd
2. Spear SL. Oncoplastic Surgery. *Plast Reconstr Surg* 2009; **124**:993-994. DOI:10.1097/PRS.0b013e3181b17ab3
3. Silverstein MJ, Mai T, Savalia N, Vaince F, Guerra L. Oncoplastic breast conservation: The new paradigm. *J Surg Oncol* 2014; **110**:82-89. DOI: 10.1002/jso.23641.
4. Hernanz F, Pérez-Cerdeira M, Sánchez S, Redondo-Figuero C. Cosmetic sequelae after breast-conserving treatment using conventional surgical techniques. *Breast J* 2013; **3**: 342-343. DOI: 10.1111/tbj. 12113

5. Petit JY, De Lorenzi F, Rietjens M, Intra M, Martella S, Garusi C, Rey PC, Matthes AG. Technical tricks to improve the cosmetic results of breast-conserving treatment. *Breast* 2007; **16**:13-16.
6. Audretsch W, Rezai M, Kolotas C. et al. Tumor-specific immediate reconstruction in breast cancer patients. *Perspect Plast Surg* 1998; **11**:71.
7. Losken A, Dugal CS, Styblo TM, Carlson GW. A meta-analysis comparing breast conservation therapy alone to the oncoplastic technique. *Ann Plast Surg* 2014; **72**: 145-149. DOI: 10.1097/SAP.0b013e3182605598
8. Haloua MH, Krekel NMA, Winters HAH et al. A systematic review of oncoplastic breast-conserving surgery. Current weaknesses and future prospects. *Ann Surg* 2013; **257**: 609-20. DOI: 10.1097/SLA.0b013e3182888782
9. Churgin S, Isakov R, Yetman R. Reconstruction options following breast conservation therapy. *Cleveland Clinic Journal of Medicine* 2008; **75**:s24-s29.
10. Munhoz AM, Montag E, Arruda E, Pellarin L, Filassi JR, Piato JR, De Barroz LC, Fonseca A, Baracat E, Ferreira MC. Assessment of immediate conservative breast surgery reconstruction: A classification system of defects revisited and a algorithm for selecting the appropriate technique. *Plast Reconstr Surg* 2008; **121**:716-727. DOI:10.1097/01.prs.0000299295.74100.fa
11. Losken A, Hamdi M. Partial breast reconstruction: current perspectives. *Plast Reconstr Surg* 2009; **124**:722-736. DOI: 10.1097/PRS.0b013e3181b179d2
12. Clough KB, Kaufman GJ, Nos C, Buccimazza I, Sarfati IM. Improving breast cancer surgery: a classification and quadrant atlas for oncoplastic surgery. *Ann Surg Oncol* 2010; **17**: 1375-1391. DOI: 10.1245/s10434-009-0792-y
13. Urban C, Lima R, Schunemann, Spautz C, Rabinovich I, Anselmi K. Oncoplastic principles in breast conserving surgery. *Breast* 2011; **20**:s92-s95.
14. McCulley, Macmillan RD. Planning and use of therapeutic mammoplasty-Notttingham approach. *BJPRAS* 2005; **58**: 889-901. DOI: 10.1016/j.bjps.2005.03.008
15. McCulley, Macmillan RD. Therapeutic mammoplasty-analysis of 50 consecutive cases. *BJPRAS* 2005; **58**:902-907. DOI: 10.1016/j.bjps.2005.03.007
16. Hernanz F, Regaño S, Vega A, et al. Reduction mammoplasty: an advantageous option for breast conserving surgery in large breasted patients. *Surg Oncol* 2010; **19**: 95-102.
17. Losken A , Pinel XA, Eskenazi BR. The benefits of partial versus total breast reconstruction for women with macromastia. *Plast Reconstr Surg* 2010; **125**: 1021-1056. DOI:10.1097/PRS.0b013e3118d0ab08
18. Munhoz AM, Montag E, Gemperli. Current aspects of therapeutic reduction mammoplasty for immediate early breast cancer management: An update. *World J Clin Oncol* 2014; **10**:1-18. DOI:10.5306/wjco.v5.i1.1
19. Hernanz F, Regaño S, Vega A, Alvarez A. Needle-wire-guided breast tumor excision. *J Surg Oncol* 2006; **94**:165-166.
20. Ballester M, Berry MG, Couturaud B, Reyat F, Salmon RJ, Fitoussi AD. Lateral mammaplasty reconstruction after surgery for breast cancer. *Br J Surg* 2009;**96**: 1141-6. DOI:10.1002/bjs.6696
21. Clough KB, Oden S, Ihrai T, Massey E, Nos C, Sarfati I. Level 2 Oncoplastic surgery for lower inner quadrant breast cancers: The LIQ-V mammoplasty. *Ann Surg Oncol* 2013. DOI: 10.1245/s10434-013-3085-4
22. Fitoussi AD, Berry MG, Famà F et al. Oncoplastic breast surgery for cancer: Analysis of 540 consecutive cases. *Plast Reconstr Surg* 2010; **125**:454-62. DOI:10.1097/PRS.0b013e3181c82d3e

23. Gucelik MA, Dogan L, Carnlibel M et al. Early complications of a reduction mammoplasty technique in the treatment of macromastia with or without breast cancer. *Clin Breast Cancer* 2011;**11**: 395-9. DOI: 10.1016/j.clbc.2011.08.001
24. Iwuchukwu OC, Harvey JR, Dordea M, Critchley AC, Drew PJ. The role of oncoplastic therapeutic mammoplasty in breast cancer surgery-A review. *Surg Oncol* 2011; **21**: 133-41. DOI: 10.1016/j.suronc.2011.01.002
25. McIntosh J, O'Donoghue JM. Therapeutic mammoplasty- A systematic review of the evidence. *EJSO* 2012; **38**: 196-202. DOI: 10.1016/j.ejso.2011.12.004
26. Kaviani A, Safavi A. Immediate and delayed contralateral symmetrization in oncoplastic breast reduction patients' choices and techniques formulation. *Plast Reconstr Surg Open* 2015; 3: e286-9. doi: 10.1197/GOX.0000000000000246.
27. Andree C, Farhadi J, Goossens D et al. A position statement on optimizing the role of oncoplastic breast surgery. *Eplasty* 2012; 12: 354-60.
28. Carty MJ, Chan R, Huckman R, Snow D, Orgill DP. A detailed analysis of the reduction mammoplasty learning curve: a statistical process model for approaching surgical performance improvement. *Plast Reconstr Surg* 2009; 124: 706-714.
29. Hernanz F, Santos R. Incorporating the surgical treatment of symptomatic macromastia into a breast cancer unit: Could this be a useful management policy? *Breast* 2011; 20:190-191. DOI: 10.16/j.breast.2010.10.006
30. Hernanz F, Santos R, Arruabarrena A, Schneider J, Gómez Fleitas M. Treatment of symptomatic macromastia in a breast unit. *World J Surg Oncol*. 2010, **8**: 93-99. doi: 10.1186/1477-7819-8-93.

References

- (1) Registro de Tumores. Dirección General de la Salud Pública. Consejería de Sanidad. Evaluación 8ª vuelta (2011-2012)
- (2) GLOBOCAN 2012. Internacional Agency for Research on Cancer
- (3) Centro Nacional de Epidemiología. Instituto de Salud Carlos III. Tendencia temporal de mortalidad ajustada a la población europea por cáncer de mama en España entre 1987 y 2007 por 100.000 habitantes.
- (4) Cotlar AM, Dubose JJ, Rose DM. 2003. *History of surgery for breast cancer: radical to the sublime*. *Curr Surg*. May-Jun;60(3):329-37.
- (5) Haloua MH, Krekel NM, Winters HA, et al., *A systematic review of oncoplastic breast conserving surgery: Current weaknesses and future prospects*, *Ann Surg*, 2013;257:609–20.
- (6) Audretsch WP. eds. *Reconstruction of the partial mastectomy defect: classification and method*. *Surgery of the breast: principles and art*. Philadelphia: Lippincott Raven, 1998.
- (7) Munhoz AM, Aldrighi CM, Ferreira MC. *Paradigms in oncoplastic breast surgery: a careful assessment of the oncological need and aesthetic objective*. *Breast J* 2007;13:326-7.
- (8) Clough C, Kaufman G, et.al. *Improving Breast Cancer Surgery: a classification and quadrant per quadrant atlas for oncoplastic surgery*. *Ann Surg Oncol*, 2010. 17:1375-1391
- (9) Urban C, et al. *Oncoplastic and Reconstructive Breast Surgery*. Springer-Verlag. Italy 2013.
- (10) McCulley, Macmillan RD. Planning and use of therapeutic mammoplasty- Nottingham approach. *BJPRAS* 2005; **58**: 889-901.DOI: 10.1016/j.bjps.2005.03.008
- (11) Urban C, Lima R, et al. *Oncoplastic principles in breast conserving surgery*. *Breast* 2011; g20(Suppl 3): S92-S95.
- (12) Hoffmann and Wallwiener. *Classifying breast cancer surgery: a novel, complexity-based system for oncological, oncoplastic and reconstructive procedures, and proof of principle by analysis of 1225 operations in 1166 patients*. *BMC Cancer* 2009 **9**:108
- (13) Clough KB, Kaufman GJ, et al. *Improving Breast Cancer Surgery: A classification and Quadrant per Quadrant Atlas for Oncoplastic Surgery*. *Ann Surg* 2010; 17:1376-1377
- (14) Chang MM, Huston T, et al. *Oncoplastic Breast Reduction: Maximizing Aesthetics and Surgical Margins*. *International Journal of Surgical Oncology*, 2012; p.3

- (15) Bulstrode NW, Shortri S. *Prediction of cosmetic outcome following conservative breast surgery using breast volume measurements*. Breast. 2001; 10: pp 539-545
- (16) American College of Radiology. *Breast imaging reporting and data systems (BIRADS)*
- (17) Fitoussi A, Berry MG, Couturaud B, Salmon RJ. *Oncoplastic and Reconstructive Surgery for Breast Cancer. The Institut Curie Experience*. 1^o ed. Berlin Heidelberg: Springer-Verlag; 2009
- (18) Dennis R. Holmes, Wesley Schooler, and Robina Smith, *Oncoplastic Approaches to Breast Conservation*, International Journal of Breast Cancer, vol. 2011, Article ID 303879, 16 pages, 2011
- (19) Acea B. Técnicas oncoplásticas. 1^o ed. La Coruña. Spain: Fundación Juan Canalejo; 2007
- (20) Yang JD, Lee JW et al. *Surgical Techniques for Personalized Oncoplastic Surgery in Breast Cancer Patients with Small-to Moderate- Sized Breasts (Part 1): Volume Displacement*. Breast Cancer. 2012 Mar; 15(1): 1–6.
- (21) Galli M, Lopez J et al. Breast cancer: Repair option by “J” technique. Cir Parag. 2014 Jun; 18: pp 12-17
- (22) Ballester M, Berry MG, Couturaud B, Reyat F, Salmon RJ, Fitoussi AD. Lateral mammaplasty reconstruction after surgery for breast cancer. Br J Surg 2009;96: 1141-6.
- (23) Moustafa A, Fakhr I. Outcome of different oncoplastic surgical (OPs) techniques for centrally located breast cancer (CLBC). J Egypt Natl Canc Inst. 2014 Dec;26(4):203-9. Epub 2014 Nov 15.
- (24) Fitoussi AD, Berry MG, Famà F et al. Oncoplastic breast surgery for cancer: Analysis of 540 consecutive cases. Plast Reconstr Surg 2010;125:454-62.