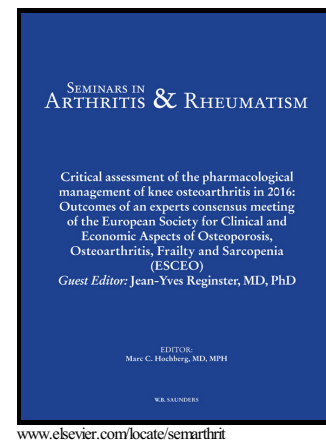


Golimumab in Refractory Uveitis Related to Spondyloarthritis. Multicenter Study of 15 Patients Golimumab in refractory spondyloarthritis-related uveitis

Vanesa Calvo-Río, Ricardo Blanco, Montserrat Santos-Gómez, Esteban Rubio-Romero, Miguel Cordero-Coma, Adela Gallego-Flores, Raúl Veroz, Ignacio Torre, Félix Francisco Hernández, Antonio Atanes, Javier Loricera, M.C. González-Vela, Natalia Palmou, José L. Hernández, Miguel A. González-Gay



PII: S0049-0172(16)00092-5  
DOI: <http://dx.doi.org/10.1016/j.semarthrit.2016.03.002>  
Reference: YSARH51029

To appear in: *Seminars in Arthritis and Rheumatism*

Received date: 2 December 2015  
Accepted date: 4 March 2016

Cite this article as: Vanesa Calvo-Río, Ricardo Blanco, Montserrat Santos-Gómez, Esteban Rubio-Romero, Miguel Cordero-Coma, Adela Gallego-Flores, Raúl Veroz, Ignacio Torre, Félix Francisco Hernández, Antonio Atanes, Javier Loricera, M.C. González-Vela, Natalia Palmou, José L. Hernández and Miguel A. González-Gay, Golimumab in Refractory Uveitis Related to Spondyloarthritis. Multicenter Study of 15 Patients Golimumab in refractory spondyloarthritis-related uveitis, *Seminars in Arthritis and Rheumatism*, <http://dx.doi.org/10.1016/j.semarthrit.2016.03.002>

This is a PDF file of an unedited manuscript that has been accepted for publication. As a service to our customers we are providing this early version of the manuscript. The manuscript will undergo copyediting, typesetting, and review of the resulting galley proof before it is published in its final citable form. Please note that during the production process errors may be discovered which could affect the content, and all legal disclaimers that apply to the journal pertain.

**GOLIMUMAB IN REFRACTORY UVEITIS RELATED TO SPONDYLOARTHRITIS.****MULTICENTER STUDY OF 15 PATIENTS**

Vanessa Calvo-Río<sup>1\*</sup>, Ricardo Blanco<sup>1\*</sup>, Montserrat Santos-Gómez<sup>1</sup>, Esteban Rubio-Romero<sup>2</sup>, Miguel Cordero-Coma<sup>3</sup>, Adela Gallego-Flores<sup>4</sup>, Raúl Veroz<sup>4</sup>, Ignacio Torre<sup>5</sup>, Félix Francisco Hernández<sup>6</sup>, Antonio Atanes<sup>7</sup>, Javier Loricera<sup>1</sup>, MC González-Vela<sup>1</sup>, Natalia Palmou<sup>1</sup>, José L. Hernández<sup>8+</sup>, Miguel A. González-Gay<sup>1+</sup>.

Rheumatology. Hospital Universitario Marqués de Valdecilla, IDIVAL, Santander, Spain<sup>1</sup>. Rheumatology. Hospital Universitario Virgen del Rocío, Sevilla<sup>2</sup>. Ophthalmology. Hospital de León<sup>3</sup>. Rheumatology Hospital de Mérida, Badajoz<sup>4</sup>. Rheumatology. Hospital Basurto. Bilbao<sup>5</sup>, Rheumatology. Hospital Doctor Negrín Canarias<sup>6</sup>. Rheumatology. HUCA La Coruña<sup>7</sup> Department of Internal Medicine, Hospital Marqués de Valdecilla, University of Cantabria-IDIVAL. Red Temática de Investigación Cooperativa en Envejecimiento y Fragilidad (RETICEF). Santander, Spain.<sup>8</sup>

\* V Calvo-Río<sup>1</sup> and R Blanco<sup>1</sup> contributed equally to this work and shared first authorship.

+ JL Hernández<sup>1</sup> and Miguel A. González-Gay<sup>1</sup> shared senior authorship.

**\* Joint corresponding authors-Address correspondence to:**

Miguel A. González-Gay or Ricardo Blanco, Rheumatology Division  
Hospital Universitario Marqués de Valdecilla,  
Avda. Valdecilla s/n., ES- 39008, Santander. SPAIN  
Email addresses: miguelaggay@hotmail.com, rblanco@humv.es

**Running Title:** Golimumab in refractory spondyloarthritis-related uveitis.

**Key indexing terms:** Spondyloarthritis, uveitis, refractory, anti-TNF-  $\alpha$  therapy, golimumab.

**ABSTRACT**

**Objective:** To assess the efficacy of golimumab (GLM) in refractory uveitis associated to spondyloarthritis (SpA).

**Methods:** Multicenter study of SpA-related uveitis refractory to at least one immunosuppressive drug. The main outcome variables were degree of anterior and posterior chamber inflammation, visual acuity, and macular thickness.

**Results:** Fifteen patients (13 men/2 women; 18 affected eyes; mean age  $39\pm6$  years) were evaluated. The underlying SpA subtypes were ankylosing spondylitis (n=8), psoriatic arthritis (n=6) and non-radiographic axial SpA (n=1). The ocular involvement patterns were recurrent anterior uveitis in 8 patients and chronic anterior uveitis in 7. Before GLM they have received methotrexate (n=13), sulfasalazine (n=6), pulses of methylprednisolone (n=4), azathioprine (n=3), leflunomide (n=2) and cyclosporine (n=1). Ten of them had also been treated with TNF- $\alpha$  blockers; etanercept (n=7), adalimumab (n=7), infliximab (n=6), and certolizumab (n=1). GLM was given at the standard dose (50 mg/sc/monthly) as monotherapy (n=7) or in combination with conventional immunosuppressive drugs (n=8), mainly methotrexate. Most patients had rapid and progressive improvement of intraocular inflammation parameters. The median number of cells in the anterior chamber at 2 years (0 [0-0]) was significantly reduced compared to baseline findings (1 [0-3]);  $p=0.04$ ). The mean best corrected visual acuity value also improved ( $0.84\pm0.3$  at 2 years versus  $0.62\pm0.3$  at baseline;  $p=0.03$ ). Only minor side effects were observed after a mean follow-up of  $23\pm7$  months.

**Conclusions:** Our results indicate that GLM may be a useful therapeutic option in refractory SpA-related uveitis.

## 1. INTRODUCTION

The term spondyloarthritis (SpA) encompasses a group of chronic inflammatory diseases characterized by joint involvement and extra-articular manifestations strongly associated with HLA B27 antigen **(1-4)**. It includes reactive arthritis (formerly called Reiter syndrome), ankylosing spondylitis (AS), inflammatory bowel disease (Crohn's disease and ulcerative colitis), undifferentiated SpA and psoriatic arthritis (PsA) **(1-4)**. Uveitis, the most common extra-articular manifestation of SpA **(5,6)**, has been included in the recently proposed classification criteria for axial and peripheral SpA **(7,8)**. The most frequent pattern of ocular involvement in SpA is a recurrent acute unilateral anterior uveitis, which usually resolves with topical therapy **(9,10)**. In some cases, however, uveitis may be refractory or relapsing, and treatment with an additional conventional immunosuppressive agents (mainly sulfasalazine or methotrexate) may be required **(9,11-13)**.

Despite using topical and conventional immunosuppressive agents, uveitis sometimes becomes chronic or relapsing leading to major ocular sequelae. According to published data, up to one-third of patients experience substantial visual impairment and up to 10% become blind **(9,10,14,15)**. Based on the recent Expert Panel Recommendations, infliximab (IFX) or adalimumab (ADA) are used when SpA-related severe, visual threatening or debilitating uveitis occurs **(9)**. These recommendations are based on several studies showing the efficacy of anti-tumor necrosis factor-alpha (anti-TNF- $\alpha$ ) agents in uveitis associated with SpA **(16-19)**. With respect to this, monoclonal antibodies seem to be more effective than the soluble receptor etanercept in most cases of uveitis **(20)** including SpA-related uveitis **(21)**.

Although IFX or ADA are the first-line recommended monoclonal antibodies for the management of SpA-uveitis refractory to conventional drugs, in some cases inadequate response, due to either intolerance or inefficacy, may be observed following the use of these two biologic agents. These patients represent a major challenge for the clinician, since no well-establish approach has been suggested to deal with these

cases. To provide an alternative therapeutic option in refractory SpA-related uveitis, we have used Golimumab (GLM), a novel fully humanized anti-TNF- $\alpha$  monoclonal antibody that has been approved for the treatment of rheumatoid arthritis, PsA, AS and ulcerative colitis (22-24). Compared to IFX, GLM is administered by subcutaneous route and has a lower risk for developing neutralizing antibodies. Moreover, it has potential advantages over ADA, as its monthly administration. However, the few published studies on the efficacy of GLM in refractory uveitis are based on small case series (25) or heterogeneous subgroups of patients with this disorder (26-32). Taking into account all these considerations, we conducted a multicenter study to analyze the clinical response to GLM in patients diagnosed with SpA-related uveitis refractory to other systemic immunosuppressive agents.

## 2. PATIENTS AND METHODS

This is an open-label, multicenter study including 15 patients with SpA-related uveitis. All of them had been refractory to previous standard synthetic immunosuppressive drugs and in some cases to at least one anti-TNF- $\alpha$  agent.

### 2.1. Working definitions

SpA was diagnosed according to the proposed classification criteria for axial or peripheral SpA (8). The diagnosis of AS was made following the modified New York criteria (33) and that of PsA according to the *Classification criteria for Psoriatic Arthritis* (CASPAR) (34).

Refractory uveitis was defined when the patient did not achieve clinical remission despite of the use of standard synthetic immunosuppressive drugs and/or anti-TNF- $\alpha$  agents or whether the treatment with these drugs was not sufficient to reach disease remission (26, 35-37).

Uveitis was classified anatomically, according to the International Uveitis Study Group (IUSG) classification (38). The degree of intraocular inflammation was evaluated

according to "The Standardization of Uveitis Nomenclature (SUN) Working Group"

(39). Nussenblatt scale was used to evaluate the degree of vitritis (40). Macular thickness was measured by optical coherence tomography (OCT). Macular thickening was defined as a macular thickness greater than 250  $\mu\text{m}$  whereas cystoid macular edema (CME) was defined as a macular thickness greater than 300  $\mu\text{m}$ . The best-corrected visual acuity (BCVA) was determined using the Snellen test.

## **2.2. GLM protocol**

GLM was given subcutaneously at the dose of 50 mg monthly. Before GLM onset, evidence of malignancy or systemic infection, including hepatitis B or hepatitis C infection, were excluded. According to the Spanish National Guidelines, in all patients receiving anti-TNF- $\alpha$  drugs, latent tuberculosis was excluded by a tuberculin skin testing (PPD) and/or quantiferon and chest radiograph. Patients with latent tuberculosis received prophylaxis with isoniazid at least 4 weeks before the onset of the biologic agent. Overall, prophylaxis was maintained for 9 months. Since GLM is an off-label indication for uveitis, written informed consent was obtained from all the patients.

## **2.3. Statistical analysis**

Clinical and laboratory variables were collected by each investigator following a protocol agreed beforehand. Categorical variables were expressed as percentages. Continuous variables were expressed as mean $\pm$ SD or as median [25th-75th interquartile range (IQR)] as appropriate, and compared by using the Wilcoxon signed-rank test. Snellen visual acuities were converted to logarithm of the minimum angle of resolution (logMAR) scores for statistical analysis.

Intraocular inflammation, macular thickness, BCVA, and sparing corticosteroid effect were the outcome variables. These variables were recorded in most patients at baseline and at 1 week, 2 weeks, 1 month, 3 months, 6 months and 1 and 2 years.

Statistical analysis was performed using the STATISTICA software (StatSoft Inc. Tulsa, Oklahoma, USA).

### 3. RESULTS

#### 3.1. *Baseline features*

Fifteen patients (18 affected eyes) with SpA-related uveitis who were treated with GLM were assessed. The main baseline characteristics of this series of patients are summarized in the **Table 1**. As expected, most patients were young men (n=13; 86.7%; mean age  $39\pm6$  years; median (range) age 39 (31- 48) years, and HLA-B27 was positive in 11 cases. The most frequent underlying SpA subtype was AS (n=8) followed by PsA (n=6) and non-radiographic axial SpA (n=1).

The most common synthetic therapy given before GLM were methotrexate (n= 13) and sulfasalazine (n=6). Four patients had received pulses of methylprednisolone. Other drugs given before GLM onset were azathioprine (n=3), leflunomide (n=2), cyclosporine (n=1). It is worth noting that 10 of these 15 patients had also been treated with TNF- $\alpha$  blockers; etanercept (n=7), adalimumab (n=7), infliximab (n=6), and certolizumab (n=1). The drugs given to each patient before the onset of GLM therapy are shown in **Table 1**.

Uveitis had been relapsing in 8 cases and chronic the other 7 cases. At GLM onset, all the patients showed active uveitis with cells in anterior chamber. Vitritis was seen in 4 cases, and CME and retinal vasculitis in 3 and 1 patient, respectively. In addition, at the time of GLM onset some patients already had visual sequelae: cataracts (n=3), cataracts and persistent CME (n=1), synechiae (n=5) and glaucoma (n=4). Besides ocular involvement, 8 patients also had active rheumatic disease.

### 3.2. GLM therapeutic scheme

**Figure 1** shows the flow chart showing all the biologic agents received by the patients included in this study. GLM was used as monotherapy in 7 cases and in combination with conventional immunosuppressive drugs in the remaining 8 patients (MTX in 5, LFN in 2, and AZA in 1 case). As described before, the standard GLM regimen was 50 mg/sc every 4 weeks. However, the dose had to be increased to 100 mg/sc every 4 weeks in 1 patient due to a new outbreak of uveitis after 4 months of GLM therapy.

### 3.3. Outcome variables

Macular thickness and BCVA showed a rapid and maintained improvement (**Figures 2A, 2B**) after GLM therapy. Thus, the mean BCVA increased from  $0.62 \pm 0.3$  before GLM onset to  $0.84 \pm 0.3$  after 2 years of treatment ( $p=0.03$ ).

Most patients had rapid and progressive improvement of intraocular inflammation parameters (anterior chamber cells, vitritis and OCT  $>250 \mu\text{m}$ ) (**Figures 3A, 3B and 3C**). In this regard, a reduction of anterior chamber cells from a median [IQR] of 1 [0-3] at baseline to 0 [0-0] at 2 years of treatment with GLM, was observed ( $p=0.04$ ).

Moreover, OCT values improved from  $295 \pm 42.2 \mu\text{m}$  at GLM onset to  $259.2 \pm 10.3 \mu\text{m}$  after 2 years of treatment, although this difference was not statistically significant ( $p=0.36$ ).

### 3.4. Other clinical findings and side-effects following GLM therapy

We have also observed a decrease, albeit non-significant, in the frequency of uveitis outbreaks that fell from 5 [3-6] outbreaks/year before GLM onset to 0.5 [0-3.5] outbreaks/year following GLM therapy ( $p=0.08$ ).

Interestingly, a corticosteroid sparing effect was also observed at 2 years (**Figure 4**). Thus, the mean daily dose of prednisone was reduced from  $34.4 \pm 19.4 \text{ mg}$  at baseline to  $9.2 \pm 7.3 \text{ mg}$  at 2 years ( $p=0.04$ ).

After a median follow-up of  $23 \pm 7$  months, 13 patients achieved complete clinical



remission. In one case, in which remission was not achieved after 26 months of treatment with GLM, this agent was withdrawn, and ADA was started with good response after 14 months of therapy. In another patient, who was in clinical remission, GLM was discontinued after 36 months of treatment because he was diagnosed with a renal adenocarcinoma. He was switched to 20 mg/day remaining asymptomatic of the uveitis since then.

Regarding the safety profile of GLM, we have observed a local injection-site reaction in 1 case, a mild facial herpes zoster which evolved favorably with oral antiviral therapy and the above mentioned case of renal adenocarcinoma.

#### 4. DISCUSSION

Herein, we report on 15 patients with SpA-related uveitis refractory to synthetic conventional immunosuppressive drugs, 10 of them also refractory to anti-TNF- $\alpha$  agents. Most of them achieved response to GLM therapy.

Uveitis prevalence in SpA ranges from 10 to 50% depending on the selected study (6, 41), the subtype of SpA (it is higher in AS and lower in undifferentiated SpA) (6), and HLA-B27 positivity (ranging between 40- 48% in HLA-B27 positive and 15-25% in HLA-B27 negative patients). (42-44).

The typical pattern in SpA-related uveitis is a unilateral, recurrent, and acute anterior involvement (45). However, there are differences in the ocular pattern depending on the subtype of SpA. Thus, uveitis in AS is usually acute, unilateral and of sudden onset. In contrast, uveitis in PsA tends to be chronic, bilateral and with insidious onset (46-49).

The prognosis of anterior uveitis is favourable in most patients. However, in some cases, especially in HLA-B27-positive patients, uveitis has less favourable outcome, and fibrin deposits in the anterior chamber, hypopyon, recurrences and sequelae, including CME, papillitis, cataracts, glaucoma, synechiae and severe vitritis, may be seen, leading to legal blindness or severe visual impairment in 10% of the patients

(14,15,50-52).

Concerning to therapy, SpA-related anterior uveitis is usually treated successfully with topical therapy that includes corticosteroids and often a dilating drop to prevent posterior synechiae and to reduce spasm of the ciliary muscle. Severe unilateral disease with a sudden onset may require locally injected corticosteroids or a brief course of oral prednisone. When uveitis is bilateral, relapsing or more severe, additional immunosuppressive therapy, mainly sulfasalazine and MTX, may be needed to achieve adequate control the disease (9, 11-13, 46).

In some patients, uveitis is refractory to these synthetic drugs, and some evidence suggests that anti-TNF- $\alpha$  monoclonal antibodies are more effective than the TNF soluble receptor (etanercept) for the treatment and prevention of uveitis (20, 21).

Paradoxically, in some cases TNF- $\alpha$  inhibitors, mainly etanercept, have been reported to cause uveitis (53, 54).

According to the Expert Panel Recommendations, IFX or ADA are the first line monoclonal anti-TNF- $\alpha$  drugs recommended to treat refractory SpA-related uveitis (9).

There are a number of studies now to prove the efficacy of these anti-TNF- $\alpha$  monoclonal antibodies in uveitis (35, 37, 55-57). This approach is based on the finding of high TNF- $\alpha$  level in the aqueous humor (58) and the inflamed joints (59) of patients with SpA. These biologic agents have shown to improve not only the musculoskeletal symptoms of SpA (60, 61) but also to prevent new outbreaks of SpA-related uveitis and to control chronic uveitis in most cases (16, 18).

Regrettably, a problem arises when refractory SpA-related uveitis has inadequate response to ADA or IFX therapy. In these cases, there is no well- established therapeutic protocol to be followed. Certolizumab has been suggested to be an effective agent to reduce frequency of SpA-related uveitis relapses, although data are scarce yet (62). On the other hand, GLM is a novel fully humanized anti-TNF- $\alpha$  monoclonal antibody approved to treat rheumatoid arthritis, PsA, AS and ulcerative colitis (22, 23, 63-65). GLM has been reported to be as a safe agent in these conditions

with a side-effect profile similar to other commercially available anti-TNF- $\alpha$  drugs (22, 66). Compared with the most commonly used anti-TNF $\alpha$  drugs, GLM has advantages in the route and periodicity of administration. Moreover, GLM is a fully human monoclonal antibody. This fact may potentially reduce the risk to develop neutralizing antibodies and allergic reactions (29-32).

There are several reports that highlight the effectiveness of GLM in immune-mediated uveitis. However, information on the efficacy of GLM in refractory SpA-related uveitis is scarce (8, 27-32). Our results indicate that GLM may be an effective therapy for SpA-related uveitis refractory to immunosuppressive drugs, also including in some cases other anti-TNF- $\alpha$  biologic agents. Moreover, besides its efficacy to maintain intraocular inflammation remission, our results suggest that GLM may be useful to prevent further relapses in SpA patients with recurrent episodes of uveitis. In this regard, our data are in keeping with the scarce published results reported in heterogeneous groups of patients with uveitis that only included a few patients with SpA (26, 27, 29). Moreover, our multicenter open-label study represents the largest series published on refractory SpA-related uveitis.

With respect to adverse side effects, although in our study we observed a case of renal carcinoma, there are many studies showing that there is no increased risk of tumors in patients treated with anti-TNF- $\alpha$  drugs. Therefore, it is possible that the occurrence of renal cancer in this case might have been an incidental finding unrelated to GLM (67).

## 5. CONCLUSION

In conclusion, our results indicate that GLM may be a useful therapeutic option in refractory SpA-related uveitis.

## 6. ACKNOWLEDGEMENTS

This work was partially supported by RETICS Program, RD12/0009/0013 (RIER) from "Instituto de Salud Carlos III" (ISCIII) (Spain).

## 7. CONFLICT OF INTEREST STATEMENT

The authors did not receive any support from commercial sources in the preparation of this manuscript.

Disclosures that might be interpreted as constituting of possible conflict(s) of interest for the study: Dr MA Gonzalez-Gay received grants/research supports from Abbott, MSD and Roche, and had consultation fees/participation in company sponsored speaker's bureau from Abbott, Pfizer, Roche, and MSD.

Disclosures that might be interpreted as constituting of possible conflict(s) of interest for the study: Dr R Blanco received grants/research supports from Abbott, MSD and Roche, and had consultation fees/participation in company sponsored speaker's bureau from Abbott, Pfizer, Roche, Bristol-Myers, Janssen and MSD.

No financial disclosure declared: Vanesa Calvo-Río, MD, PhD, Montserrat Santos-Gómez, MD, Esteban Rubio-Romero, MD, Miguel Cordero Coma, MD, FEBOphth, Adela Gallego-Flores, MD, Raúl Veroz, MD, Ignacio Torre, MD, Félix Francisco Hernández, MD, Antonio Atanes, MD, Javier Loricera, MD, MC González-Vela, MD, PhD, Natalia Palmou, MD, PhD and José L. Hernández, MD, PhD.

## 8. FUNDING

This work was also partially supported by RETICS Programs, RD08/0075 (RIER) and RD12/0009/0013 from "Instituto de Salud Carlos III" (ISCIII) (Spain)

**9. REFERENCES**

1. Gladman DD. Psoriatic arthritis. *Rheum Dis Clin North Am* 1998; 24:829-44.
2. De Keyser F, Elewaut D, De Vos M, et al. Bowel inflammation and the spondyloarthropathies. *Rheum Dis Clin North Am* 1998; 24: 785-813.
3. Gladman D. Spondyloarthropathies. In: Lahita R, Weinstein A, eds. Educational review manual in rheumatology. 2d ed. rev. New York: Castle Connolly Graduate Medical, 2002: 1-26.
4. Healy PJ, Helliwell PS. Classification of the spondyloarthropathies. *Curr Opin Rheumatol*. 2005; 17:395.
5. Mielants H, Van den Bosch F. Extra-articular manifestations. *Clin Exp Rheumatol* 2009; 27 (Suppl. 55): S56-61.
6. Zeboulon N, Dougados M, Gossec L. Prevalence and characteristics of uveitis in the spondyloarthropathies: a systematic literature review. *Ann Rheum Dis* 2008; 67: 955-9.
7. Rudwaleit M, van der Heijde D, Landewé R et al. The development of Assessment of SpondyloArthritis international Society classification criteria for axial spondyloarthritis (part II): validation and final selection. *Ann Rheum Dis* 2009; 68: 777-84.
8. Rudwaleit M, van der Heijde D, Landewé R et al. The Assessment of SpondyloArthritis international Society classification criteria for peripheral spondyloarthritis and for spondyloarthritis in general. *Ann Rheum Dis* 2011; 70:25-31.
9. Levy-Clarke G, Jabs DA, Read RW et al. Expert panel recommendations for the use of anti-tumor necrosis factor biologic agents in patients with ocular inflammatory disorders. *Ophthalmology*. 2014; 121:785-96.
10. Rosenbaum JT. Uveitis in spondyloarthritis including psoriatic arthritis, ankylosing spondylitis, and inflammatory bowel disease. *Clin Rheumatol*. 2015; 34: 999-1002.

11. Muñoz-Fernández S, Hidalgo V, Fernández-Melón J et al. Sulfasalazine reduces the number of flares of acute anterior uveitis over a one-year period. *J Rheumatol.* 2003; 30:1277-9.
12. Dougados M, Berenbaum F, Maetzel A, Amor B. Prevention of acute anterior uveitis associated with spondylarthropathy induced by salazosulfapyridine. *Rev Rhum Ed Fr.* 1993; 60:81-3.
13. Muñoz-Fernández S, García-Aparicio AM, Hidalgo MV et al. Methotrexate: an option for preventing the recurrence of acute anterior uveitis. *Eye (Lond).* 2009; 23:1130-3.
14. Chang JH, McCluskey PJ, Wakefield D. Acute anterior uveitis and HLA-B27. *Surv Ophthalmol.* 2005; 50:364-88.
15. Power WJ, Rodriguez A, Peroza-Seres M, Foster CS. Outcomes in anterior uveitis associated with the HLAB27 haplotype. *Ophthalmology.* 1998; 105: 1646–1651.
16. Braun J, Baraliakos X, Listing J, Sieper J. Decreased incidence of anterior uveitis in patients with ankylosing spondylitis treated with the anti-tumor necrosis factor agents infliximab and etanercept. *Arthritis Rheum* 2005; 52: 2447-51.
17. Sieper J, Koenig A, Baumgartner S, et al. Analysis of uveitis rates across all etanercept ankylosing spondylitis clinical trials. *Ann Rheum Dis.* 2010; 69: 226-9.
18. Rudwaleit M, Rodevand E, Holck P, et al. Adalimumab effectively reduces the rate of anterior uveitis flares in patients with active ankylosing spondylitis: results of a prospective open-label study. *Ann Rheum Dis* 2009; 68:696-701.
19. Rosenbaum JT, Rudwaleit M, Landewe R, et al. Observed Incidence Rates of Uveitis over 96 Weeks of Certolizumab Pegol Treatment in Patients with Axial Spondyloarthritis. *Arthritis Rheum* 2014; 66; S10:S237.

20. Galor A, Perez VL, Hammel JP, Lowder CY. Differential effectiveness of etanercept and infliximab in the treatment of ocular inflammation. *Ophthalmology*. 2006; 11:2317-23.
21. Guianard S, Gossec L, Salliot C, et al. Efficacy of tumour necrosis factor blockers in reducing uveitis flares in patients with spondylarthropathy: a retrospective study. *Ann Rheum Dis*. 2006; 65:1631-4.
22. Kay J, Rahman MU. Golimumab: a novel human anti-TNF $\alpha$  monoclonal antibody for the treatment of rheumatoid arthritis, ankylosing spondylitis, and psoriatic arthritis. *Core Evid* 2010; 4:159-170.
23. Smolen JS, Kay J, Doyle MK et al. Golimumab in patients with active rheumatoid arthritis after treatment with tumor necrosis factor  $\alpha$  inhibitors (GO-AFTER study): a multicentre, randomised, double-blind, placebo-controlled, phase III trial. *Lancet* 2009; 374: 210-21
24. Emery P, Fleischmann RM, Moreland LW et al. Golimumab, a human anti-tumor necrosis factor  $\alpha$  monoclonal antibody, injected subcutaneously every four weeks in methotrexate-naïve patients with active rheumatoid arthritis. Twenty-four-week results of a phase III, multicenter, randomized, double-blind, placebo-controlled study of golimumab before methotrexate as first-line therapy for early-onset rheumatoid arthritis. *Arthritis Rheum* 2009; 60:2272-83.
25. Faez S, Lobo AM, Sobrin L, Papaliodis GN. Treatment of seronegative spondyloarthropathy-associated uveitis with golimumab: retrospective case series. *Clin Experiment Ophthalmol*. 2014; 42:392-5.
26. Calvo-Río V, de la Hera D, Blanco R et al. Golimumab in uveitis previously treated with other anti-TNF- $\alpha$  drugs: a retrospective study of three cases from a single centre and literature review. *Clin Exp Rheumatol*. 2014; 32:864-8.
27. Cordero-Coma M, Calvo-Río V, Adán A et al. Golimumab as rescue therapy for refractory immune-mediated uveitis: a three-center experience. *Mediators Inflamm* 2014; 2014:717598.

28. Miserocchi E, Modorati G, Pontikaki I, Meroni PL, Gerloni V. Long-term treatment with golimumab for severe uveitis. *Ocul Immunol Inflamm* 2014; 22:90-5.
29. Miserocchi E, Modorati G, Pontikaki I, Meroni P, Gerloni V. Golimumab treatment for complicated uveitis. *Clin Exp Rheumatol* 2013; 31:320-1.
30. Cordero-Coma M, Salom D, Díaz-Llopis M, López-Prats MJ, Calleja S. Golimumab for uveitis. *Ophthalmology* 2011; 118:1892.
31. William M, Faez S, Papaliodis GN, Lobo AM. Golimumab for the treatment of refractory juvenile idiopathic arthritis-associated uveitis. *J Ophthalmic Inflamm Infect* 2012; 2:231-3.
32. Mesquida M, Hernández MV, Llorenç V, et al. Behçet disease-associated uveitis successfully treated with golimumab. *Ocul Immunol Inflamm* 2013; 21:160-2.
33. Van der Linden S, Valkenburg H, Cats A: Evaluation of diagnostic criteria for ankylosing spondylitis. A proposal for modification of the New York criteria. *Arthritis Rheum* 1984; 27:361-368.
34. Taylor W, Gladman D, Helliwell P, et al. Classification criteria for psoriatic arthritis: development of new criteria from a large international study. *Arthritis Rheum*. 2006; 54:2665-2673.
35. Díaz-Llopis M, Salom D, Garcia-de-vicuña C, et al. Treatment of refractory uveitis with adalimumab: a prospective multicenter study of 131 patients. *Ophthalmology* 2012; 119:1575-81.
36. Calvo-Río V, de la Hera D, Beltrán-Catalán E. et al. Tocilizumab in uveitis refractory to other biologic drugs: a study of 3 cases and a literature review. *Clin Exp Rheumatol*. 2014; 32 (4 Suppl 84):S54-7.
37. Calvo-Río V, Blanco R, Beltrán E, et al. Anti-TNF- $\alpha$  therapy in patients with refractory uveitis due to Behçet's disease: a 1-year follow-up study of 124 patients. *Rheumatology (Oxford)*. 2014; 53:2223-31.



38. Deschenes J, Murray PI, Rao NA, Nussenblatt RB. International Uveitis Study Group (IUSG) clinical classification of uveitis. *Ocul Immunol Inflamm* 2008;16:1-2.
39. The standardization of uveitis nomenclature (SUN) working group; Standardization of Uveitis Nomenclature for Reporting Clinical Data. Results of the First International Workshop. *J Ophthalmol* 2005; 140:509-516.
40. Nussenblatt RB, Palestine AG, Chan CC, Roberge F. Standardization of vitreal inflammatory activity in intermediate and posterior uveitis. *Ophthalmology* 1985; 92 467-71.
41. Sampaio-Barros PD, Pereira IA, Hernández-Cuevas C, et al. An analysis of 372 patients with anterior uveitis in a large Ibero-American cohort of spondyloarthritis: the RESPONDIA Group. *Clin Exp Rheumatol*. 2013; 31:484-9.
42. Maksymowych WP, Adlam N, Lind D, Russell AS. Polymorphism of the LMP2 gene and disease phenotype in ankylosing spondylitis: no association with disease severity. *Clin Rheumatol* 1997; 16:461-5.
43. Feldtkeller E, Khan MA, van der Heijde D, van der Linden S, Braun J. Age at disease onset and diagnosis delay in HLA-B27 negative vs. positive patients with ankylosing spondylitis. *Rheumatol Int* 2003; 23:61-6.
44. Jaakkola E, Herzberg I, Laiho K, et al. Finnish HLA studies confirm the increased risk conferred by HLA-B27 homozygosity in ankylosing spondylitis. *Ann Rheum Dis* 2006; 65:775–80.
45. Bañares A, Jover JA, Fernández-Gutiérrez B, et al. Patterns of uveitis as a guide in making rheumatologic and immunologic diagnoses. *Arthritis Rheum*. 1997;40:358-70.
46. Rosenbaum JT. Characterization of uveitis associated with spondyloarthritis. *J Rheumatol*. 1989;16:792-6;

47. Sampaio-Barros PD, Conde RA, Bonfiglioli R, Bértolo MB, Samara AM. Characterization and outcome of uveitis in 350 patients with spondyloarthropathies. *Rheumatol Int.* 2006; 26:1143-6.
48. Durrani K, Foster CS. Psoriatic uveitis: a distinct clinical entity? *Am J Ophthalmol.* 2005; 139:106-11.
49. Fraga NA, Oliveira Mde F, Follador I, Rocha B de O, Rêgo VR. Psoriasis and uveitis: a literature review. *An Bras Dermatol.* 2012; 87:877-83.
50. Rothova A, Buitenhuis HJ, Christiaans BJ, et al: Acute anterior uveitis (AAU) and HLA-B27. *Br J Rheumatol.* 1983;22:144-5.
51. Tay-Kearney ML, Schwam BL, Lowder C, et al. Clinical features and associated systemic diseases of HLA-B27 uveitis. *Am J Ophthalmol.* 1996;121:47–56.
52. Rothova A, Suttorp-van Schulten MS, Frits Treffers W, Kijlstra A. Causes and frequency of blindness in patients with intraocular inflammatory disease. *Br J Ophthalmol.* 1996;80:332-6.
53. Wendling D, Paccou J, Berthelot JM, et al. New onset of uveitis during anti-tumor necrosis factor treatment for rheumatic diseases. *Semin Arthritis Rheum.* 2011;4:503-10.
54. Lim LL, Fraunfelder FW, Rosenbaum JT et al. Do tumor necrosis factor inhibitors cause uveitis? A registry-based study. *Arthritis Rheum.* 2007; 56: 3248-52.
55. Riancho-Zarrabeitia L, Calvo-Río V, Blanco R et al. Anti-TNF- $\alpha$  therapy in refractory uveitis associated with sarcoidosis: Multicenter study of 17 patients. *Semin Arthritis Rheum.* 2015:21.
56. Arida A, Fragiadaki K, Giavri E, Sfikakis PP. Anti-TNF agents for Behçet's disease: analysis of published data on 369 patients. *Semin Arthritis Rheum* 2011; 41:61-70.

57. Sobrin L, KIM EC, Christen W, Papadaki T, Letko E, Foster CS. Infliximab therapy for the treatment of refractory ocular inflammatory disease. *Arch Ophthalmol*. 2007; 125:895-900.
58. Santos Lacombe M, Marcos Martin C, Gallardo Galera JM, et al. Aqueous humor and serum tumor necrosis factor-alpha in clinical uveitis. *Ophthalmic Res* 2001; 33:251-5.
59. Braun J, de Keyser F, Brandt J, Mielants H, Sieper J, Veys E. New treatment options in spondyloarthropathies: increasing evidence for significant efficacy of anti-tumor necrosis factor therapy. *Curr Opin Rheumatol* 2001; 13:245-9.
60. Braun J, Brandt J, Listing J, et al. Treatment of active ankylosing spondylitis with infliximab: a randomised controlled multicentre trial. *Lancet* 2002; 6:1187-93.
61. Poddubnyy D, Rudwaleit M. Adalimumab for the treatment of ankylosing spondylitis and nonradiographic axial spondyloarthritis - a five-year update. *Expert Opin Biol Ther*. 2013; 13:1599-611.
62. James T. Rosenbaum, Martin Rudwaleit, Robert B. M. Landewe, et al. Observed Incidence Rates of Uveitis over 96 Weeks of Certolizumab Pegol Treatment in Patients with Axial Spondyloarthritis. *Arthritis Rheum* 2014; 66; S10:S237.
63. Kavanaugh A, McInnes I, Mease P, et al. Golimumab, a new human tumor necrosis factor alpha antibody, administered every four weeks as a subcutaneous injection in psoriatic arthritis: Twenty-four-week efficacy and safety results of a randomized, placebo-controlled study. *Arthritis Rheum* 2009; 60:976-86.
64. Inman RD, Davis JC JR, Heijde D, et al. Efficacy and safety of golimumab in patients with ankylosing spondylitis: results of a randomized, double-blind, placebo-controlled, phase III trial. *Arthritis Rheum* 2008; 58:3402-12.

65. Sandborn WJ, Feagan BG, Marano C, et al. Subcutaneous golimumab induces clinical response and remission in patients with moderate-to-severe ulcerative colitis. *Gastroenterology*. 2014; 146:85-95.
66. Schoels M, Aletaha D, Smolen JS, Wong JB. Comparative effectiveness and safety of biological treatment options after tumour necrosis factor  $\alpha$  inhibitor failure in rheumatoid arthritis: systematic review and indirect pairwise meta-analysis. *Ann Rheum Dis*. 2012; 71:1303-8.
67. Carmona L, Abasolo L, Descalzo MA et al. Cancer in patients with rheumatic diseases exposed to TNF antagonists. *Semin Arthritis Rheum*. 2011; 41:71-80.

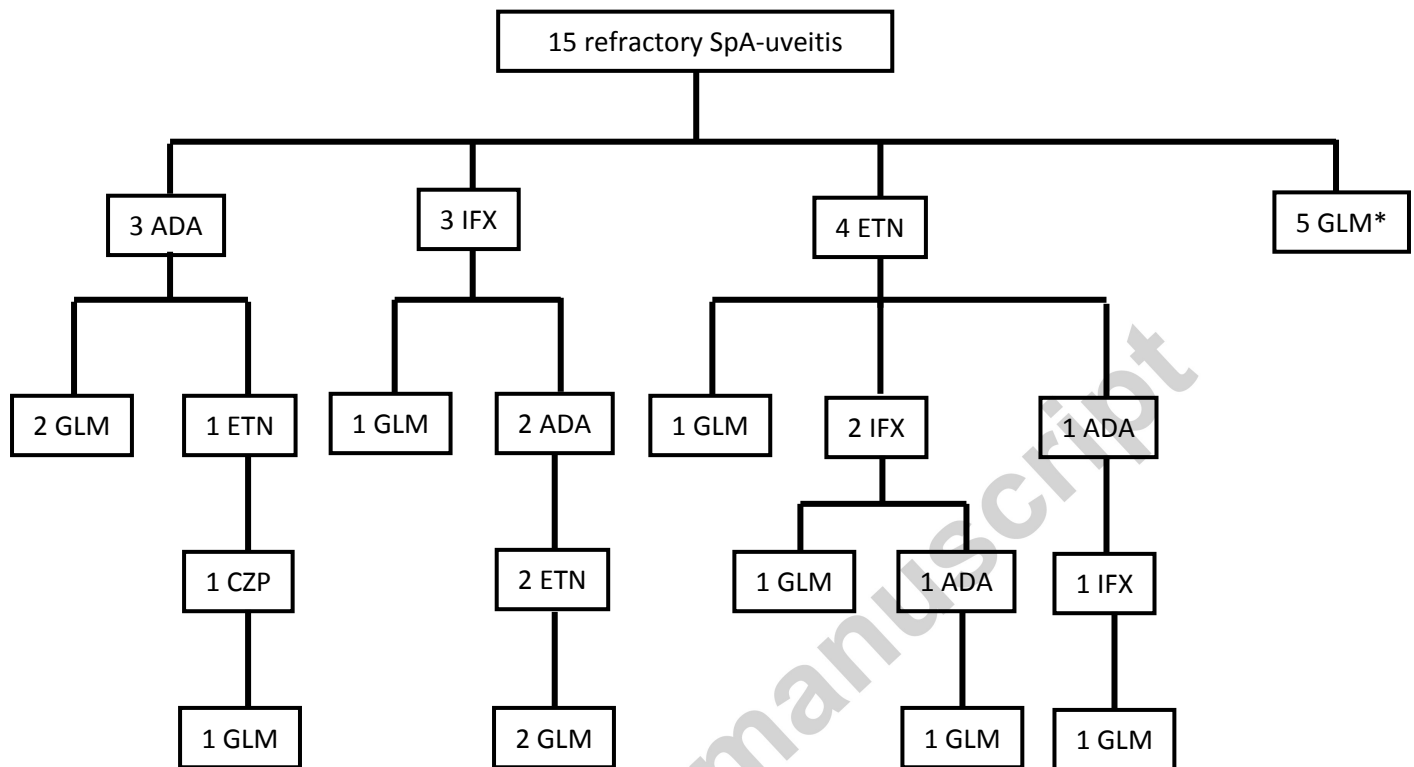
**TABLE 1.** Main epidemiological, underlying spondyloarthritis (SpA), treatment and ophthalmologic features of a series of 15 patients with SpA undergoing golimumab therapy because of uveitis refractory to other immunosuppressive drugs (IS).

Patient	Age	Sex	HLA-B27	Subtype of SpA	Pattern of Uveitis	Ocular involvement	Previous IS to GLM	Indication for GLM
1	37	Man	+	AS	AU/ chronic/ unilateral	AC cells + vitritis + CME	MTX, SSZ	uveitis
2	32	Man	+	AS	AU/ chronic/ bilateral	AC cells + CME	MTX, SSZ, ADA	uveitis
3	45	Man	+	AS	AU/recurrent / unilateral	AC cells + CME	IFX, ADA, ETN	uveitis
4	46	Man	+	AS	AU chronic/ bilateral	AC cells + vitritis	MTX	uveitis and articular activity
5	48	Man	+	AS	AU chronic/ unilateral	AC cells	MTX, ETN, IFX	uveitis and articular activity
6	42	Man	+	AS	AU recurrent/ unilateral	AC cells + vitritis	MTX, AZA, ETN	uveitis and articular activity
7	47	Man	+	AS	AU recurrent/ unilateral	AC cells	MTX, AZA, LFN, SSZ, IFX	uveitis and articular activity
8	39	Man	+	AS	AU recurrent/ unilateral	AC cells	SSZ , AZA	uveitis and articular activity
9	36	Man	+	PsA	AU recurrent/ unilateral	AC cells + vitritis	MTX, SSZ, ADA	uveitis and articular activity
10	31	Woman	-	PsA	AU recurrent/ unilateral	AC cells	MTX, ADA, ETN, CZP, ETN	uveitis and articular activity
11	36	Man	-	PsA	AU chronic/ unilateral	AC cells	MTX, IFX, ADA, ETN	uveitis
12	32	Man	+	PsA	AU chronic/	AC cells	MTX,	uveitis

					unilateral		LFN, ETN, IFX, ADA	and psoriasis
<b>13</b>	35	Woman	-	PsA	AU chronic/ unilateral	AC cells	MTX, SSZ	uveitis and articular activity
<b>14</b>	40	Man	+	PsA	AU recurrent/ unilateral	AC cells + retinal vasculitis	MTX, CsA, ETN, ADA, IFX	uveitis
<b>15</b>	43	Man	-	nr- axSpA	AU recurrent/ unilateral	AC cells	MTX	uveitis

**Abbreviations:** **AS**=ankylosing spondylitis; **nr-axSpA**=non radiographic axial spondyloarthritis; **PsA**=psoriatic arthritis; **AU**= anterior uveitis; **AC cells**=anterior chamber cells; **CME**= cystoid macular edema; **MTX**=methotrexate; **SSZ**=salazopyrin; **IFX**=infliximab; **ADA**=adalimumab; **ETN**= etanercept; **AZA**=azathioprine; **CZP**=certolizumab; **LFN**=leflunomide; **CsA**=cyclosporine

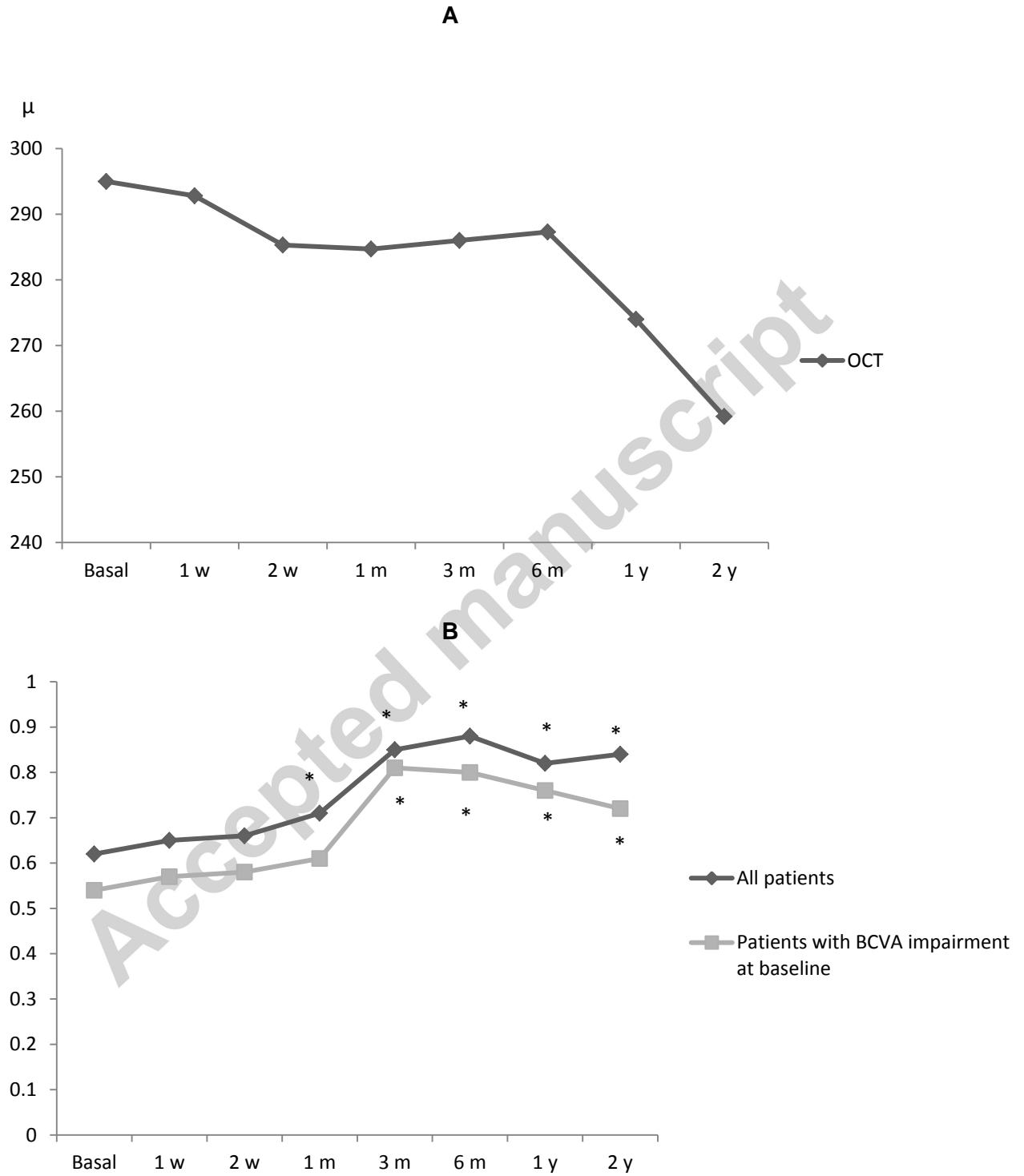
**FIGURE 1.** Flow-chart of 15 patients with refractory uveitis related to spondyloarthritis undergoing golimumab therapy.



**Abbreviations:** IFX=infliximab; ADA= adalimumab; ETN= etanercept; CZP= certolizumab;  
GLM= golimumab

\*In one patient GLM was switched to ADA due to inefficacy

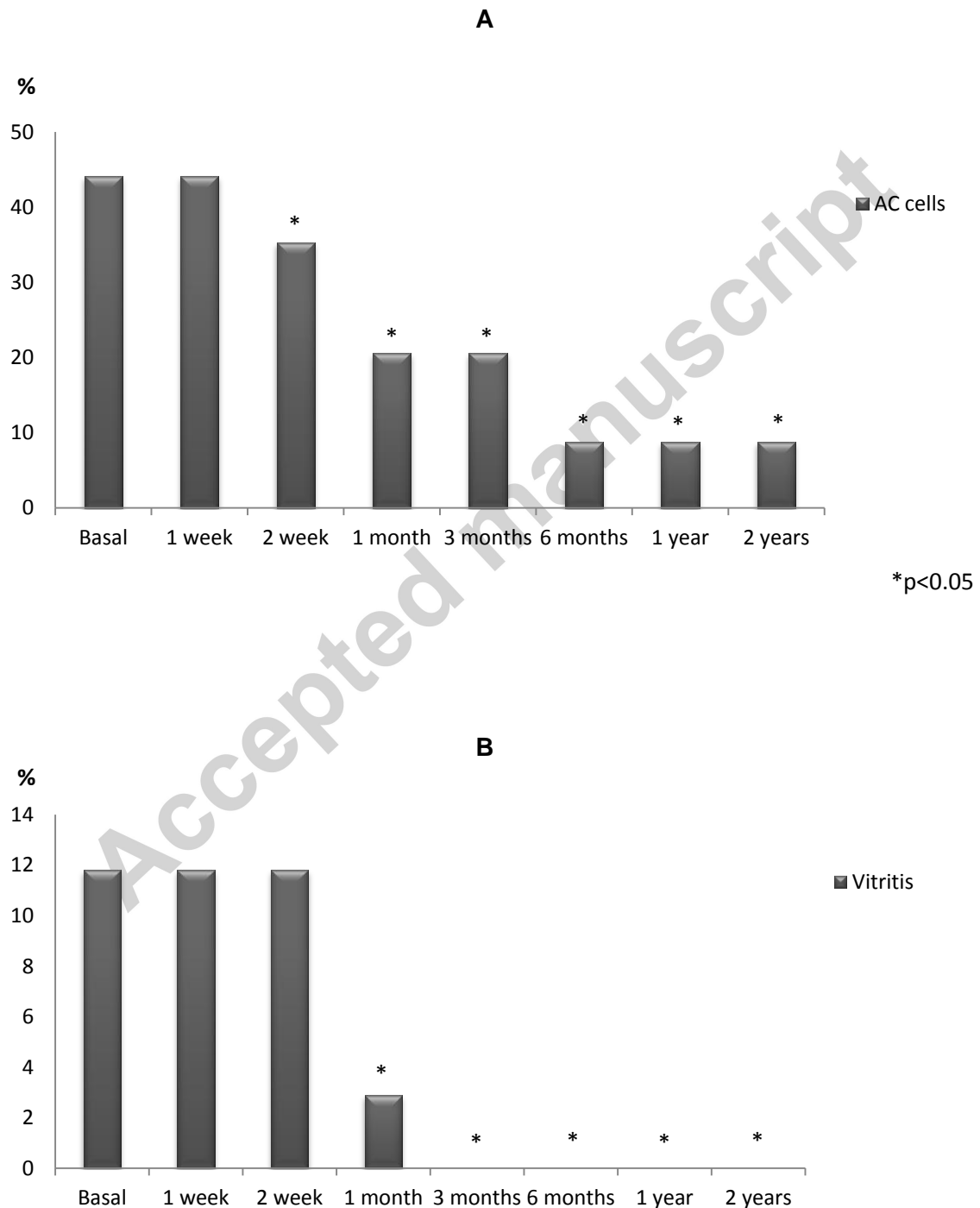
**FIGURE 2.** Rapid and maintained improvement following the onset of GLM therapy (data expressed as mean values compared with basal results): **(A)** macular thickness and **(B)** best corrected visual acuity (BCVA).



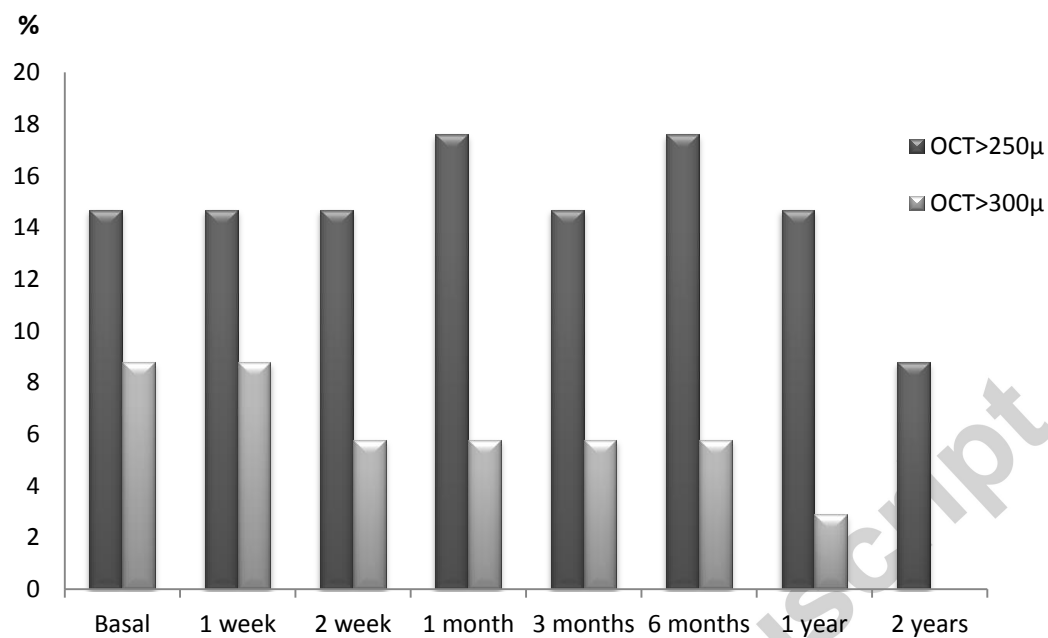
\*p<0.05



**FIGURE 3.** Golimumab therapy led to improvement of active inflammation of: **(A)** Anterior chamber cells (AC cells), **(B)** vitritis and **(C)** OCT values. Data were expressed when any score of activity was present as percentage of affected eyes. Active inflammation was considered if: AC cells > 0, vitritis > 0 and optical coherence tomography >250 microns.



c



**FIGURE 4.** Sparing corticosteroid-sparing effect following GLM therapy in a series of refractory SpA-related uveitis (values are expressed as mean of prednisone/day).

